

Original Article

Molecular Identification of Fowl Adenovirus Associated with Inclusion Body Hepatitis in Iran

Hosseini H^{1*}, Morshed R²

1. Department of Clinical Sciences, Faculty of Veterinary Medicine, Islamic Azad University, Karaj Branch, Karaj, Iran.
2. Agriculture and Veterinary group, Iranian institute for encyclopedia research, Ministry of science, research and technology, Tehran, Iran.

Abstract

Background and Aims: Inclusion body hepatitis (IBH) is one of the most important reemerging diseases in many countries with intensive poultry industries. In Iran, the etiological agent of IBH (fowl adenovirus) has not been yet confirmed. The aim of this study was the molecular detection and identification of fowl adenovirus involving IBH in chicken flocks in Iran.

Materials and Methods: Polymerase chain reaction (PCR) and sequence analysis of L1 hexon gene was utilized to detect and to determinate the genotypes of Fowl adenovirus (FAdV) in broiler breeder flocks. Histopathological sections were prepared and examined.

Results: FAdVs were detected in livers. Based on sequencing analysis of the hexon gene, they were genetically related to FAdV-11, a member of the fowl adenovirus D species, with 98% homology to Korean strain in 2011. Histological examination revealed necrotizing hepatitis with basophilic intranuclear inclusion bodies in the hepatocytes.

Conclusion: This study provided evidence for the role of fowl adenoviruses as agents, causing this clinical disease in Iran and indicated the importance of accurate diagnosis and prevention in the meat-type flocks.

Keywords: Inclusion Body Hepatitis (IBH); Fowl Adenovirus Serotype 11; Breeder; Iran

Introduction

Inclusion body hepatitis (IBH) was first described in 1963 in USA (1). The disease has been reported in many other countries in the world. In recent years, reemergence of IBH has increased the importance of adenoviruses infection in the poultry industries.

Fowl adenoviruses (FAdVs) of the genus Aviadenovirus are the cause of hepatitis in

birds even though other agents may also be involved. The FAdVs have been grouped into 5 different species (A–E) based on the molecular criteria and sequencing data, and into 12 serotypes (1–8a & 8b–11) based on the cross-neutralization tests (2). Many different serotypes have been associated with natural outbreaks of IBH, in particular those belonging to the species E can cause severe liver damage which is leading to IBH (2).

Immunosuppression induced by infectious bursal disease virus (IBDV) and chicken anemia virus (CAV) or some mycotoxins, such as aflatoxins appear to assist adenoviruses in producing IBH (3–5). However, there are many evidences that IBH can be a primary disease in chickens (6–10) and apparently IBH can

*Corresponding author: Hosseini H, Ph.D. Department of Clinical Sciences, Faculty of Veterinary Medicine, Islamic Azad University, Karaj Branch, Karaj, Iran.
Email: hosseini.ho@gmail.com

possibly occur without the influence of infectious immunosuppression (11).

IBH is usually seen in meat-producing birds between three and seven weeks of age. Morbidity is low and Mortality usually ranges between 5% and 10%, but it can reach 30 % (12-14). The main postmortem finding is pale, friable and swollen liver with multiple petechial hemorrhage (15-17). Icterus is mostly seen in skin over the legs, breasts and subcutaneous fat (18). In the majority of outbreaks, eosinophilic intranuclear inclusions are found in the hepatocytes while otherwise basophilic inclusions are detected infrequently (19).

Diagnosis of the IBH is based on the isolation and identification of adenoviruses. Serological tests, such as double immunodiffusion and ELISA, can be used. Molecular methods, especially PCR, have been widely applied to detect and allocate isolates to the species and to the serotypes (2). The usage of PCR followed by restriction enzyme digestion or sequencing of the products allows the differentiation of field isolates from the presumptive serotypes (20, 21). Recently, the combination of PCR and high resolution melting (HRM) curve analysis has provided an accurate and rapid genotyping technique for the identification of FAdV serotypes in the field cases of IBH (22, 23).

Recently, high rate of mortality in the first three weeks of life has been reported in some of the Iranian flocks. The aim of this study was the molecular detection and identification of a Adenovirus which is involved in the field cases of IBH in Iran.

Methods

Case history

High rate of mortality in male flocks of two broiler breeder farms has occurred in two different parts of the country. All male flocks were originated from the same grandparents (GP), and were less than three weeks old. Chickens were clinically reported to show depression and their mortality stood between 20 and 30 percent. At necropsy, gross lesions

were consisted of enlarged and pale yellow liver with multiple petechial hemorrhages. Interestingly, there was no clinical signs and mortality or even in female flocks. Adenovirus vaccines are not commercially available in Iran, so none of chicken flocks were vaccinated against adenoviruses.

Histopathological examination

For histopathological examination, livers from the suspected chickens were fixed in 10% buffered formalin, embedded in paraffin, sectioned at 4 μ m, stained with hematoxylin and eosin and examined by light microscopy (24).

DNA extraction

DNA was extracted directly from the 20 infected liver tissues (10 samples from each farm according to the previously described method (22). Briefly, 50 mg liver tissues were placed in 400 μ l RLT buffer for 2h at 4°C to be lysed. DNA was extracted by spin columns, bedded with Qiaex II suspension matrix beads (Qiagen) and dissolved in 50 μ l diethylpyrocarbonate (DEPC)-treated water.

Molecular Detection

Amplification of a 590 bp region of the hexon gene was done by PCR to confirm the presence of viral DNA. One set of primer binding to Hex Loop1 (L1) gene was used to amplify L1. The primers were forward primer: Hex L1-s 5'- ATGGGAGCSACCTAYTTCGACAT-3' and reverse primer: Hex L1-as 5'- AAATTGTCCCKRAANCCGATGTA-3'. A 25 μ l reaction consisted of 4 μ l of dNTPs at 1.25 mM, 2 μ l of each primer at 25 μ M, 5 μ l of 5X PCR Buffer, 1.25 U of DNA Polymerase (Cinnacolne, Iran), 2 μ l of extracted viral DNA and 2 μ l of 25 mM MgCl₂. PCR assays were performed in Gradient Palm Cycler (Corbett Life Science Pty Ltd). The conditions of the PCR were denaturation step of 94° for 2 min, followed by 40 cycles consisting of 94°C for 20 s, 56°C for 20 s and 72°C for 30 s as described by steer *et al* (22). The PCR products were analyzed on 1.5% agarose gels containing ethidium bromide. The electrophoresis was performed at 100 Volts for 30 to 40 min in 1 X TAE buffer. After electrophoresis, PCR products were visualized by a transilluminator.

DNA from Australian FAdV-8b vaccine strain (Intervet Pty Ltd) was used as positive control.

DNA sequencing of the PCR product and phylogenetic analysis

PCR together with DNA sequencing have been used for accurate FAdV typing. PCR product was purified using the high pure PCR product purification Kit (Roche, Germany) according to the manufacturer s’ instructions. Purified PCR products were sequenced in a forward and in a reverse direction. Sequencing reactions were performed with the ABI Prism BigDye Terminator Cycle Sequencing Ready Reaction Kit (Applied Biosystems, USA) as described by the manufacturer. The nucleotide sequences of Hexon genes determined in this study were compared to the FAdV sequence data available in the NCBI database, and the phylogenetic relationship was established. All of the sequences were aligned using the ‘CLUSTAL W’. Distance-based neighbor joining trees were constructed using the Tamura–Nei model available in the program MEGA5, version 5 (25). The robustness of the phylogenetic trees was assessed by 1,000 bootstrap replicates. Bootstrap support of C70% was shown near the nodes in the phylogenetic trees (27).

Gene Submission

The sequences of hexon protein gene of IR-HM-1/2011 and IR-HM-1/2011 have been deposited under accession numbers KF406339 and KF406340 in Gene bank.

Results

The histopathological examination of livers revealed hepatitis with multifocal areas of necrosis and the presence of large basophilic intranuclear inclusion bodies in the necrotic hepatocytes (figure 1).

Presence of the virus was confirmed by PCR amplification of a 590bp fragment from the entire 20 clinical samples (figure 2). Primers hexon L1-s and L1-as allowed the amplification of the expected 590bp DNA fragment between nucleotides 301 and 890 of the FAdV field isolates that is type-specific domains in loop 1 of the hexon of fowl adenoviruses (28).

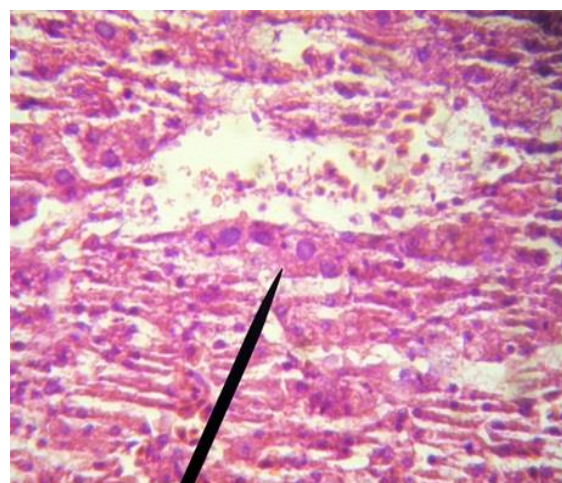


Fig. 1. Histopathological examination of livers from chickens with IBH. A hematoxylin and eosin stained section of liver showing basophilic intranuclear inclusion bodies (arrow), 100 x magnification.

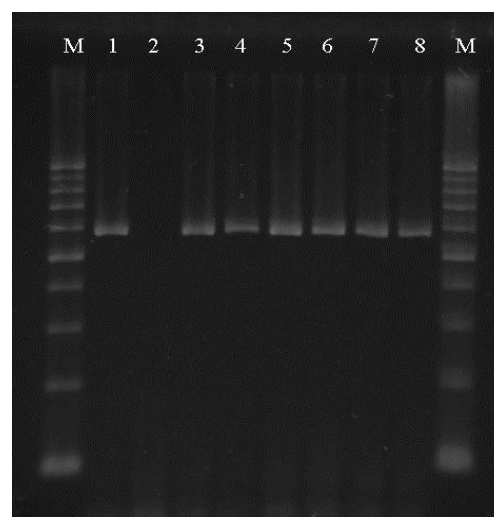


Fig. 2. Amplification of Hexon gene of FAdV : M: GeneRuler 100bp DNA Ladder, (Fermentas. Canada), Lane 1: Positive Control, Lane 2: Negative Control, Lane 3-8: clinical samples.

Amplicons generated from the field isolates were sequenced. Phylogenetic analysis of hexon gene sequences isolates from two farms belonged to genotype D/serotype 11 and shared 98% homology with the Korea strain (figure 3).

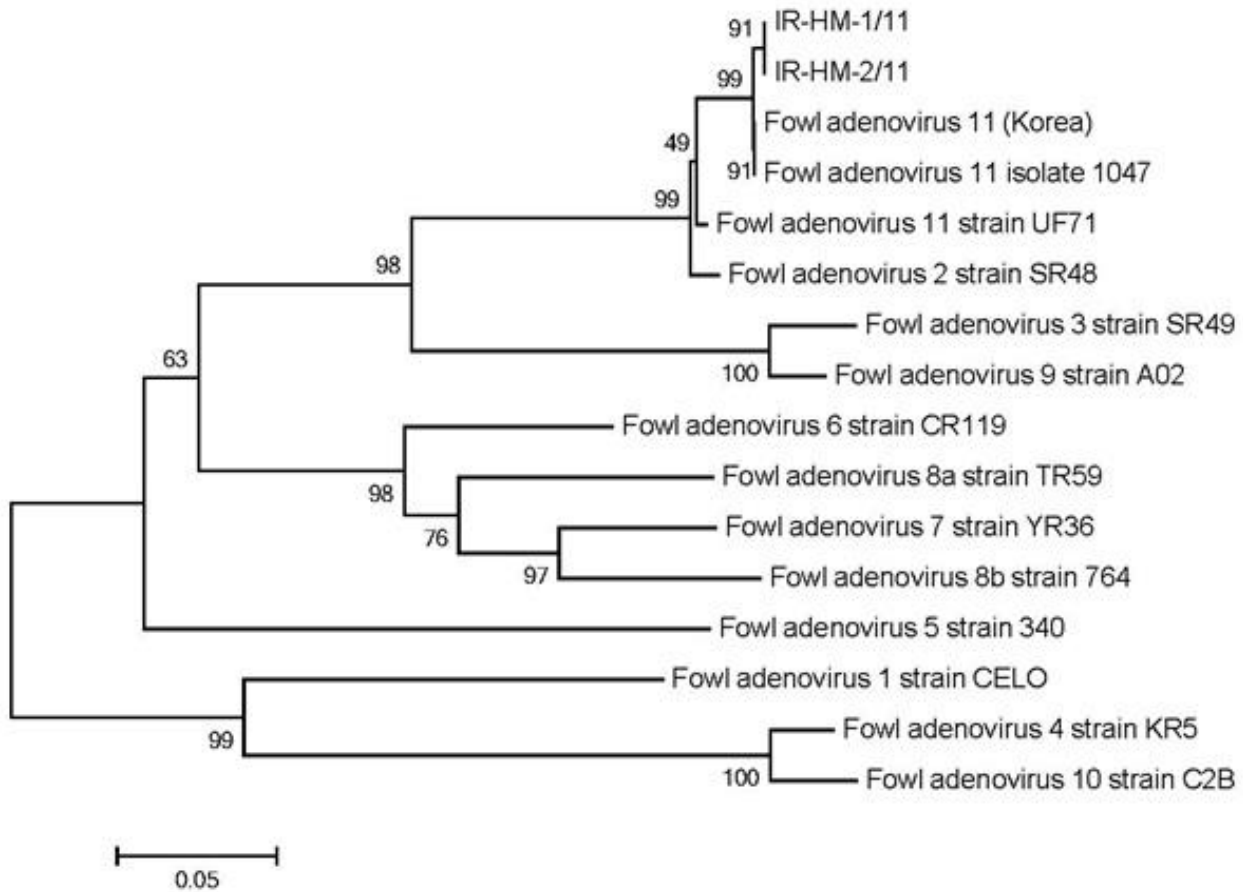


Fig. 3. FAdV phylogenetic tree of the L1 loop of the hexon gene. The tree is based on the sequence of the hexon gene from the two FAdV isolates and the 14 reference strains. FAdV isolates used in this study are marked in bold.

Discussion

Inclusion body hepatitis (IBH) has been occurring as an economically important and reemerging disease of broiler breeder and broiler chickens in several countries (9, 24, 29-32). Although the IBH outbreaks are usually associated with serotype 6, 7, and 8, the viruses associated with outbreaks in Iran were adenovirus serotype 11, based on hexon gene sequencing of the PCR products (20). We used molecular methods for diagnosis of adenovirus, serotypes and identifying the origin of adenovirus strain in IBH.

It is the first report of IBH and with identification of the causative virus from two outbreaks in broiler breeders in Iran. In our study, we identified FAdV-11 serotype of field isolates originating from 3 week-old chickens. This serotype was isolated from swollen pale

yellow livers in farms showing up to 30% mortality. It can suggest that this serotype can cause clinical diseases and mortality in chickens as seen in other countries. FAdVs associated with IBH outbreaks in Canada from 2000 to 2006 were genetically related to FAdV02 (nine isolates, 99.4%), FAdV08a (100 isolates, 99.4% to 100%) and FAdV11 (98 isolates, 99.4% to 100%) by hexon gene loop 1 sequencing (33). In 2003, the Fowl Adenovirus isolates in Ontario, Canada matched Serotype 11(380 strain) in group D genotype (34). FAdV-11 strain 1047 was responsible for IBH outbreaks in Saskatchewan, Canada (33). Another study in 2007 detected 18 FAdV-11 among 55 fowl adenovirus from different flocks in Korea with 99% homology to 1047 strain (30). Fowl adenovirus serotype 11 had also been found in Hungary in 2010 (35).

We couldn't detect IBDV and CAV in the clinical samples. Historically, IBH has been identified as a secondary disease, often associated with common immunosuppressive diseases. CAV and IBDV have most often been found to be predisposing factors to IBH outbreaks (29). But recently, many cases of IBH with highly pathogenic virus types as primary pathogens have also been described (9, 31, 33). Studies conducted in Canada, the USA, New Zealand, and Australia indicated that IBH occurred as a primary disease with no association with IBDV or CIAV. It appears that IBH as primary disease is a new finding and needs more attention.

The studies in Canada supported the hypothesis that IBH in broilers is a vertically-transmitted primary disease with no known immunosuppressive involvement (9, 36). Sequencing analysis has revealed that involving serotypes in two flocks are the same. On the other hand, male flocks that were originated from the same GP flocks and transferred to two different geographical areas, showed IBH clinical signs in the first weeks of life. Taking all together, it may suggest that the virus may vertically transfer to progeny. Vertical transmission of FAdV associated with IBH has been detected in the USA (37) and in Canada (9). This finding emphasizes the need for the development of improved control strategy especially in parent flocks.

In conclusion, Serotype 11 fowl adenovirus was identified as the causative agent of IBH in two young broiler breeder flocks in Iran. This report provides evidence of the role of fowl adenoviruses as agents causing clinical diseases with moderate mortality in meat-type chickens and points out the importance of accurate diagnosis in every instance.

Acknowledgment

We would like to thank experts of PCR Veterinary Diagnostic Laboratory for their technical supports.

References

1. Helmboldt CF and Frazier MN. Avian hepatic inclusion bodies of unknown significance *Avian Dis.* 1963;7:446-450.
2. Fitzgerald SV. Adenovirus Infections In: *Diseases of Poultry*, 12th Ed, Saif, YM, AM Fadly, JR Glisson, LR McDougald, LK Nolan and DE Swayne, eds Iowa State University Press, Iowa, USA. 2008;251- 266.
3. Fadly AM, Winterfield RW, Olander HJ. Role of the bursa of Fabricius in the pathogenicity of inclusion body hepatitis and infectious bursal disease viruses. *Avian Dis.* 1976;20:467-472.
4. Bülow von V, Rudolph R and Fuchs B. Folgen der Doppeltinfektion von Küken mit Adenovirus oder Reovirus und dem Erreger der infektiösen Anämie. *J Vet Med B.* 1986;33:717-726.
5. Shivachandra SB, Sah RL, Singh SD, Kataria JM, Manimaran K. Immunosuppression in broiler chicks fed aflatoxin and inoculated with fowl adenovirus serotype-4 (FAV-4) associated with hydropericardium syndrome. *Vet Res Commun.* 2003;27:39-51.
6. Christensen NH & Saifuddin M. A primary epidemic of inclusion body hepatitis in broilers. *Avian Dis.* 1989;33:622-630.
7. El-Attrache J, Villegas P. Genomic identification and characterization of avian adenoviruses associated with inclusion body hepatitis. *Avian Dis.* 2001;45:780-787.
8. Erny KM, Barr DA, Fahey KJ. Molecular characterization of highly virulent fowl adenoviruses associated with outbreaks of inclusion body hepatitis. *Avian Pathol.* 1991; 20: 597-606.
9. Gomis S, Goodhope R, Ojkić D, Willson P. Inclusion body hepatitis as a primary disease in broilers in Saskatchewan, Canada. *Avian Dis.* 2006;50:550-5.
10. Reece RL, Barr DA, and Grix DC. Pathogenicity studies with a strain of fowl adenovirus serotype 8 (VRI-33) in chickens. *Aust Vet J.* 1987;64(12):365-367.
11. Zavala G, Dufour-Zavala L, Villegas P, El-Attrache J, Hilt DA, Jackwood MW. Lack of interaction between Avian Leukosis virus subgroup J and Fowl Adenovirus (FAV) in FAV-Antibody-Positive chickens. *Avian Dis.* 2002; 46: 979-984.
12. McFerran JB, Smyth JA. Avian adenoviruses. *Rev Sci Tech.* 2000;19:589-606.
13. Anjum AD, Sabri MA, Iqbal Z. Hydropericarditis syndrome in broiler chickens in Pakistan. *Vet Rec.* 1989;124:247-248.

14. Cowen B. Inclusion body hepatitis-anemia and hydropericardium syndromes: aetiology and control. *World's Poult Sci J.* 1992; 48: 247-254.
15. Howell J, McDonald DW, Christian RG. Inclusion body hepatitis in chickens. *Can Vet J.* 1970;11:99-101.
16. Macpherson I, McDougall JS, Laursen-Jones AP. Inclusion body hepatitis in a broiler integration. *Vet Rec.* 1974;95:286-289.
17. McFerran JB & Adair BM. Avian adenoviruses—a review. *Avian Pathol.* 1977;6:189-217.
18. Asrani RK, Gupta BK, Sharma SK, Singh SP and Katoch RC. Hydropericardium hepatopathy syndrome in Asian poultry. *Vet Rec.* 1997;141:271-273.
19. Itakura C, Matsushita S, Goto M. Fine structure of inclusion bodies in hepatic cells of chickens naturally affected with inclusion body hepatitis. *Avian pathol.* 1977;6:19-32.
20. Meuleman G, Boschmans M, van den Berg TP, Decaesstecker M. Polymerase chain reaction combined with restriction enzyme analysis for detection and differentiation of fowl adenoviruses. *Avian Pathol.* 2001;30:655-60.
21. Jiang P, Ojkic D, Tuboly T, Huber P, Nagy . Application of the polymerase chain reaction to detect fowl adenoviruses. *Can J Vet Res.* 1999;63:124–128.
22. Steer PA, Kirkpatrick NC, O' Rourke D, Noormohammadi AH. Classification of fowl adenovirus serotype by use of high resolution melting-curve analysis of the hexon gene region. *Journal of clinical microbiology.* 2009;311-321.
23. Steer PA, O' Rourke D, Ghorashi S A, Noormohammadi AH. Application of high-resolution melting curve analysis for typing of fowl adenoviruses in field cases of inclusion body hepatitis. *Australian veterinary journal.* 2011;89(4): 1-9.
24. Okuda Y, Ono M, Yazawa S, Shibata I, and Sato S. Experimental infection of specific-pathogen-free chickens with serotype-1 fowl adenovirus isolated from a broiler chicken with gizzard erosions. *Avian Dis.* 2001;45:19–25.
25. Tamura K, Peterson D, Peterson N, Stecher G, Nei M, and Kumar S. MEGA5: Molecular Evolutionary Genetics Analysis using Maximum Likelihood, Evolutionary Distance, and Maximum Parsimony Methods. *Molecular Biology and Evolution.* 2011;28:2731-2739.
26. Noteborn MHM, Verschueren CAJ, van Roozelaar DJ, Veldkamo S, van der Eb AJ, Boer GF. Detection of chicken anemia virus by DNA hybridization and polymerase chain reaction. *Avian Pathol.* 1992;21:107-18.
27. Cao YC, Yeung WS, Bi YZ, Leung FC, Lim BL. Molecular characterization of seven Chinese isolates of infectious bursal disease virus: classical, very virulent, and variant strains. *Avian Dis.* 1998;42:340-51.
28. Toogood CI, Crompton J, Hay RT. Antipeptide antisera define neutralizing epitopes on the adenovirus hexon. *J Gen Virol.* 1992;73(Pt 6):1429–1435.
29. Toro H, Gonzales C, Cerda L, Hess M, Reyes E, Geisse C. Chicken anemia virus and fowl adenoviruses: association to induce the inclusion body hepatitis/hydropericardium syndrome. *Avian Dis.* 2000;44:51-8.
30. Lim TH, Lee HJ, Lee DH, Lee YN, Park JK, Youn HN, et al. Identification and virulence characterization of fowl adenoviruses in Korea. *Avian Dis.* 2011;55(4):554-560.
31. Ojkić D, Krell PK, Tuboly T, Nagy E. Characterization of fowl adenoviruses isolated in Ontario and Quebec, Canada. *Can J Vet Res.* 2008a; 72:236-41.
32. Steer PA and Noormohammadi AH. Inclusion Body Hepatitis Outbreaks in Australian Meat Breeder and Broiler Flocks. RIRDC Publication, Australia, 2011.
33. Ojkic D, Martin E, Swinton J, Vaillancourt J P, Boulianne M, and Gomis S. Genotyping of Canadian isolates of fowl adenoviruses. *Avian Pathol.* 2008b;37(1):95-100.
34. Manthan, P. Inclusion body hepatitis (IBH) experience in broilers in Ontario. 2003: www.canadianpoultryca/cms_pdfs/IBH_Final1pdf
35. Lagstad SF. Identification and preliminary characterization of fowl adenovirus from field cases. *Hungarian Veterinary Arch.* 2010: <http://www.whu.vetahu/handle/10832/330>
36. Ekanayake S. Inclusion body hepatitis as a primary disease in commercial broiler chickens. A Thesis Submitted to the College of Graduate Studies for the Degree of Master of Science. In the Department of Veterinary Pathology, University of Saskatchewan, Saskatoon, Canada. 2009;43-45.
37. Pilkington P, Brown T, Villegas P, McMurray B, Page RK, Rowland GN, Thayer SG. Adenovirus-induced inclusion body hepatitis in four-day-old broiler breeders *Avian Dis.* 1997;41:472–474.