

## Case Report

# Detection of the Chinese Genotype of Infectious Bronchitis Virus (QX-type) in Iran

Bozorgmehri-Fard MH<sup>1</sup>, Charkhkar S<sup>1</sup>, Hosseini H<sup>2,3\*</sup>

1. Department of Clinical Science, Faculty of Veterinary Medicine, Islamic Azad University, Science and Research Branch, Tehran, Iran.

2. Department of Clinical Sciences, Faculty of Veterinary Medicine, Islamic Azad University, Karaj Branch, Karaj, Iran.

3. PCR Veterinary Diagnostic Laboratory, No. 6, Khodro Allay, Golbar Avi., Tohid Sq., Tehran, Iran.

### Abstract

**Case Report:** Recently a 20-day-old layer flock with mortality has been submitted to the PCR Lab. Infectious Bronchitis Virus (IBV) has been detected in the clinical samples.

**Results:** A phylogenetic tree based on a partial S1 gene sequence showed Iranian IBV variant located in LX4-type cluster. This cluster include all QXIBV-type detected in China and European countries. The highest sequence homology (> 99%) was found with that of a group of the Chinese QX but less similarity with European QX-like (>95%) and another Chinese QXIBV (>94%).

**Conclusion:** Comparison of Nucleotides sequence with H120 and 4/91 IB vaccines shows only 76.9 and 79.7 identity, respectively.

**Keywords:** Infectious Bronchitis Virus (IBV); Clinical Samples; Phylogenetic Tree

### Introduction

Infectious bronchitis virus (IBV) is prevalent in most parts of the world where intensive poultry industry operates. This coronavirus causes a highly contagious respiratory disease in chickens. Nevertheless, the virus can affect the kidney and reproductive tract (1). Being the largest known RNA virus, IBV has a great ability to create different forms of antigenic and genotypic types by genetic recombination and spontaneous mutation. If genetic changes occur in hypervariable region of the spike (S) gene, new variant may emerge. Even tiny changes in

the genome may lead to the appearance of new serotype and protectotype (1).

Only Massachusetts and 793/B serotypes of IBV have been reported from Iran. Moreover, several reports have emphasized the continuing dominance of 793/B serotype (2-4). However, it is possible that there exist more different IB variants in Iran, since specific primers have been used in these studies (1). Since 2010, clinical samples suspected to be Infectious Bronchitis (IB) have been submitted to PCR Veterinary Diagnostic Laboratory (Tehran, Iran). In the lab, detection and strain identification of IBV has been conducted using high-resolution melting curve analysis (HRM). New variants of IBV detected by using HRM have been reported consequently (5).

The primary aim of this investigation was to identify the new variant of infection bronchitis virus in Iran.

\*Corresponding author: Hosseini H, Ph.D. Department of Clinical Sciences, Faculty of Veterinary Medicine, Islamic Azad University, Karaj Branch, Karaj, Iran.  
Email: hosseini.ho@gmail.com

## Case Presentation

Recently a 20-day-old layer flock with mortality has been submitted to the PCR Veterinary Diagnostic Laboratory (Tehran, Iran). Application of a Real-Time PCR following HRM analysis revealed that an unidentified IBV is circulating in the poultry farms in Iran. With the intention of further characterization of the new virus, partial S1 gene amplified and sequenced.

Total RNA was extracted according to the previously described method (6). To describe briefly, the clinical samples were placed in 400µl RLT buffer with 1% B-mercaptoethanol for 2h at 4°C to be lysed. RNA extracted by spin columns bedded with Qiaex II suspension matrix beads (Qiagen) and made clear in 50µl diethylpyrocarbonate (DEPC)-treated water. The protocols and primers previously described have been used to amplify S1 (7). The PCR products were detected by gel electrophoresis (BioRad, United State) in 1% agarose (UltraPure Agarose, invitrogen) gel in TBE buffer. PCR products were then purified using High Pure PCR Product Kit (Roche, Germany) according to manufacture instructions. PCR products were sequenced in both directions. The nucleotide sequences were aligned and edited using MEGA5 (8).

The nucleotide sequences were aligned with sequence of known strains of IBV to find the exact relationship among them. Phylogenetic and molecular evolutionary analyses were conducted using MEGA version 5 (8).

## Results

Comparative analysis of partial S1 nucleotide sequence was performed to find similarities among the new virus identified in Iran (submitted to GenBank, accession JX477827) and different strains of IB including commercial vaccines available in Iran. The highest sequence homology (>99%) which was detected with that of a group of Chinese QX (ck/CH/LSD/090708) was not found as high with another Chinese QXIBV (>94%) and European QX-like (>95%). Upon comparison between Nucleotides sequences, only 76.9 and

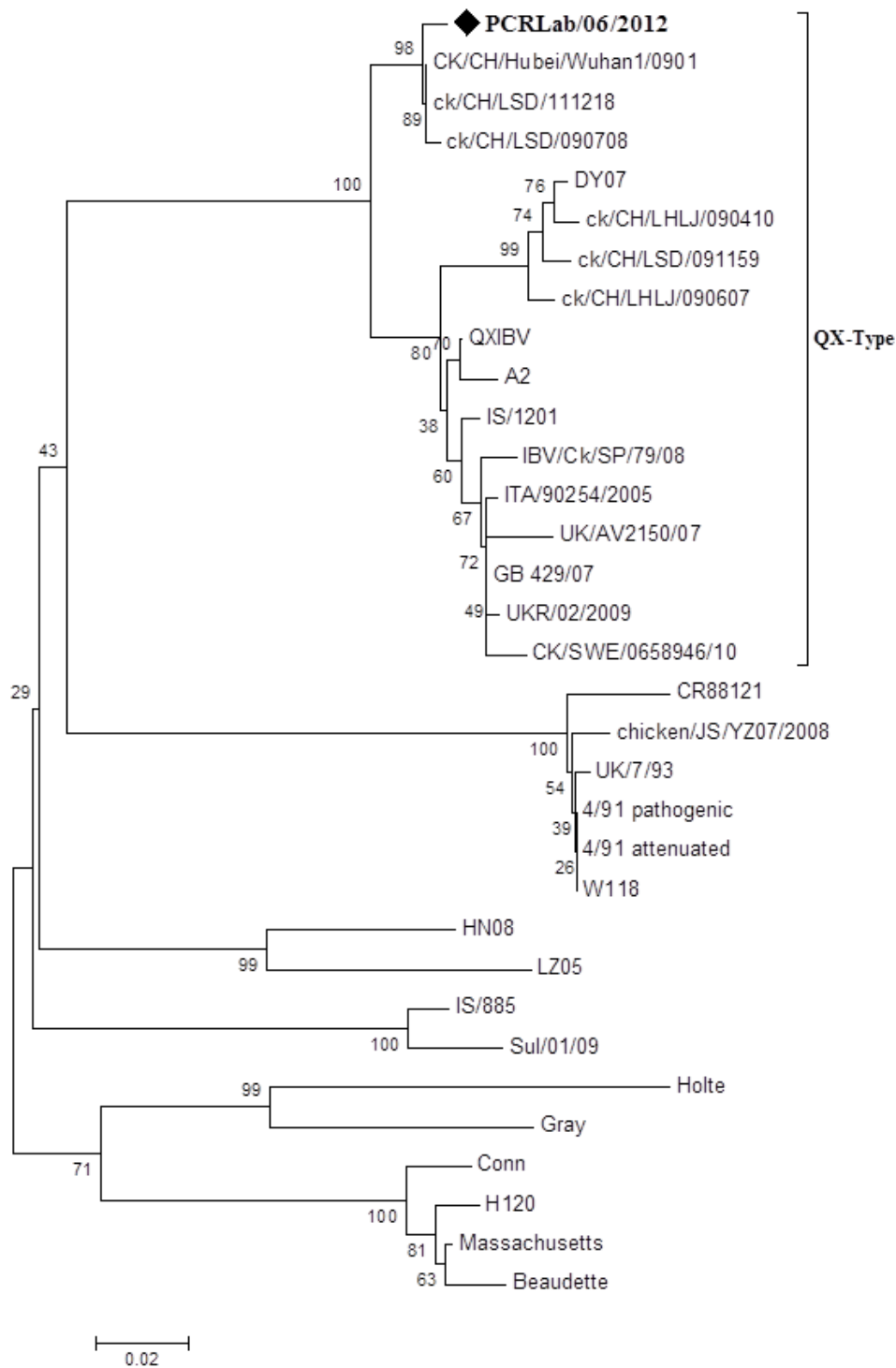
79.7 identity was shown respectively with H120 and 4/91 IB vaccines.

The report delivered in this article is, to our best knowledge, the first local one confirming the presence of QXIBV-type in Iran. A phylogenetic tree based on a partial S1 gene sequence showed Iranian IBV variant located in A2-type or LX4-type cluster (Fig. 1). This cluster include all QXIBV-type formerly detected in China and European countries (9-11).

## Discussion

Historically, Infectious bronchitis virus has been known as a respiratory pathogen. Later, other clinical manifestations and postmortem signs associated with IBV have been reported. The virus can cause significant reduction in egg production and quality and also kidney damage. Abnormal oviduct at sexual maturity has been known as a consequence of early expose of female chicks to IBV from long time ago. Highly undifferentiated and immature oviduct may be affected by IBV. Epithelial cells in oviduct are the target ones. Damage due to IBV infection can result in permanent disorder in oviduct. Affected birds do not lay at sexual maturity and known as “false layers”. Affected flocks fail to reach a satisfactory egg production rate. Variation in virulence for oviduct among the IBV's has been reported. Massachusetts and T strains have shown virulence for oviduct (12,13). Since 2003, a new variant associate with “false layer” has continually been detected in Europe. The IBV QX genotype was first detected in China in 1988. Clinical signs associated with QX strain include proventiculitis and nephritis in China and “false layer” and nephritis in European countries (10). Experimental evidence showed that Chinese QX caused oviduct damage like the European QX-like viruses (14). In the present case, interestingly, twenty-one days after the detection of IBV, the dilated oviduct filled with serum-like fluid was obvious at postmortem examination (Fig. 2).

It is also fair to say that not only have the origin of this virus and the means through which it was introduced to Iran been unclear to

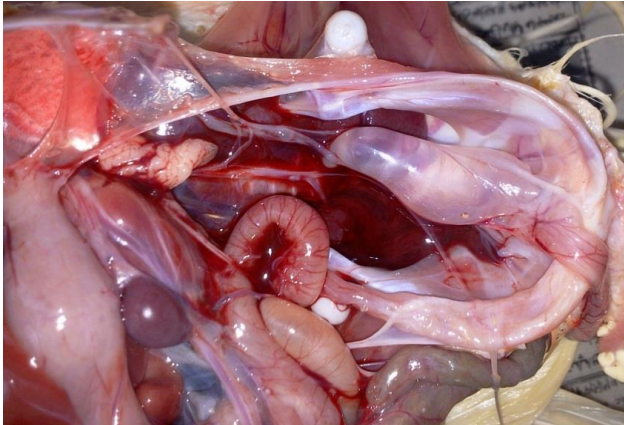


**Fig. 1.** Nucleic acid based phylogenetic relationships of partial spike gene of infectious bronchitis virus detected in Iran. The Phylogenetic tree was generated using neighboring joining model with MEGA. The virus characterized in this report is indicated as Black diamond. The sequences were obtained from the Gene Bank.

date and in need of more scrutiny, but also the prevalence rate of the new virus among Iranian chicken flock is yet to be further studied.

However, as for the former, considering the replication of IBV in Anseriforms, it has been hypothesized that these wild birds may serve as

[Downloaded from journal.isv.org.ir on 2023-12-10] [DOI: 10.21859/isv.7.1.2.57]



**Fig. 2.** Accumulation of serum-like fluid in dilated oviduct in the 41-day-old layer (i.e. 21 days since the detection of IBV).

media of dissemination of the virus to a new faraway geographic place (15)

### Acknowledgment

We would like to thank PCR Veterinary Diagnostic Laboratory experts for their technical support.

### References

1. Wit D, Cook J, Heijden H. Infectious bronchitis virus variants: a review of the history, current situation and control measures. *Avian Pathology*. 2011;40:223-235.
2. Seify-Abad-Shapouri MR, Mayahi M, Charkhkar S, Assasi K. Serotype Identification of Recent Iranian Isolates of Infectious Bronchitis Virus by Type-Specific Multiplex RT-PCR. *Archives of Razi Institute*. 2002; 53:79-85.
3. Seyfi-Abad-Shapouri MR, Mayahi M, Assasi K, Charkhkar S. A survey of the prevalence of infectious bronchitis virus type 4/91 in Iran. *Acta Veterinaria Hungarica*. 2004;52:163-166.
4. Shoushtari AH, Toroghi R, Momayez R, Pourbakhsh SA. 793/B type, the predominant circulating type of avian infectious bronchitis viruses 1999-2004 in Iran: a retrospective study. *Archives of Razi Institute*. 2008;63:1-5.
5. Hosseini H, Noormohammadi A. Rapid Detection and Identification of New Strains of Infectious Bronchitis Virus in Field Specimens by High-Resolution Melting analysis. proceeding of 3<sup>rd</sup> international veterinary poultry congress. 2012.
6. Hewson K, Noormohammadi AH, Devlin JM, Mardani K., Ignjatovic J. Rapid detection and non-subjective characterisation of infectious bronchitis virus isolates using high-resolution melt curve analysis and mathematical model. *Arch Virol*. 2009;154:649-660.
7. Worthington K J, Currie RJ., Jones R. A reverse transcriptase-polymerase chain reaction survey of infectious bronchitis virus genotypes in Western Europe from 2002 to 2006. *Avian Pathol*. 2008;37:247-257.
8. Tamura K, Peterson D, Peterson N, Stecher G, Nei M, Kumar S. MEGA5: Molecular Evolutionary Genetics Analysis using Maximum Likelihood, Evolutionary Distance, and Maximum Parsimony Methods. *Molecular Biology and Evolution*. 2011; 28:2731-39.
9. Zou NL, Zhao FF, Wang YP, Liu P, Cao SJ, Wen XT, Huang Y. Genetic analysis revealed LX4 genotype strains of avian infectious bronchitis virus became predominant in recent years in Sichuan area, China. *Virus Genes*. 2010; 41: 202-209
10. Abro SH, Renström LH, Ullman K, Belák S, Baule C. Characterization and analysis of the full-length genome of a strain of the European QX-like genotype of infectious bronchitis virus. *Arch Virol*. 2012;157:1211-1215.
11. Ji J, Xie J, Chen F, Shu D, Zuo K, Xue C, Qin J, Li H, Bi Y, Ma J, Xie Q. Phylogenetic distribution and predominant genotype of the avian infectious bronchitis virus in China during 2008-2009. *Virol J*. 2011;22:184-193
12. Broadfoot DI, Pomeroy BS, Smith WM. Effects of infectious bronchitis in baby chicks. *Poultry Science*.1956;35:757-762.
13. Crinion R AP, Ball RA, Hofstad MS. Abnormalities in laying chickens following exposure to infectious bronchitis virus at one day old. *Avian Diseases*. 1971;15:42-48.
14. Benyeda Z, Szeredi L, Mato T, Suveges T, Balka G, Abonyi-Toth Z, Rusvai M, Palya V. Comparative Histopathology and Immunohistochemistry of QX-like, Massachusetts and 793/B Serotypes of Infectious Bronchitis Virus Infection in Chickens. *Journal of comparative pathology*.2010;143:276-283.
15. Bochkov YA, Batchenko GV, Shcherbakova LO, Borisov AV, Drygin VV. Molecular epizootiology of avian infectious bronchitis in Russia.2006; *Avian Pathol*. 35:379-393.