

## Original Article

# Respiratory Syncytial Virus Infection in Children Referred to Kasra Hospital in Tehran during the Period of 2012-2014

Ataei-Pirkooh A<sup>1</sup>, Shahrabadi MS<sup>1\*</sup>, Ahmadi E<sup>2</sup>

1. Virology Department, Faculty of Medicine, Tehran University of Medical Sciences, Tehran, Iran.
2. Virology Department, Faculty of Medical Sciences, Tarbiat Modares University, Tehran, Iran.

## Abstract

**Background and Aims:** Respiratory syncytial virus (RSV) infection is common in infants and young children. In infants younger than one year old it may cause bronchiolitis and pneumonia which requires hospitalization. Accurate and rapid diagnosis of the disease will help proper treatment of the disease and prevent further complications.

**Materials and Methods:** Specimen taken from respiratory tract of sick children were processed and fixed for immunofluorescence staining. Monoclonal antibody conjugate specific for RSV was used and the specimens were examined by a UV microscope.

**Results:** In this study most of the infection occurred during the winter month such as Nov, Dec and Jan. From 168 patients, 111 referred from Dec to Feb and 51% of them were positive. Most of the patient were under one year and the majority were up to 8 month old. However there was one patient, a 36 old woman which was positive indicating that RSV infection can occur in adults. There were no significant changes in infection between the males and females.

**Conclusion:** The results of this study showed that disease is common during the winter time in children in Tehran and a rapid reliable test such as immunofluorescence should be applied for prompt detection of the disease and its proper treatment.

**Keywords:** Respiratory Syncytial Virus (RSV), Monoclonal antibody, Immunofluorescence staining.

## Introduction

One of the most severe respiratory tract infection in infants and young children is caused by respiratory syncytial virus (1). The virus which was isolated (2) in 1956 from an infants suffering from respiratory infection belongs to the family of Paramyxoviridae, order Mononegavirales. It contains a single stranded negative sense RNA

genome which multiplies in the cytoplasm of host cell. During multiplication the virus produces large intra cytoplasmic inclusions which contain viral antigens detectable by serological method. The virus can grow in cultured cells and produce cytopathic effect which appear as syncytium formation. The viral genome encodes 10 proteins among which the F protein is a fusion protein causing cell fusion and giant cell formation (3). The virus affects mostly the children younger than one year old but it can infect older children and adults. Most of the infected children develop bronchiolitis or pneumonia which some of them will require hospitalization (4, 5). The disease occurs mainly in winter month mostly

\*Corresponding author: Mahmoud Shamsi-Shahrabadi, PhD, Department of Virology, Faculty of Medicine, Tehran of Medical Sciences, Tehran, Iran.  
Tel/Fax: (+98)-21 88602205  
Email: Mshahrabadi@hotmail.com

in January and February (6, 7), but can also happen in other seasons in tropical areas (8, 9). In epidemic season which starts in October till April, most of the infected children develop bronchiolitis and other respiratory tract infection (10). In a previous study we reported RSV infection rate during cold seasons in some areas in Tehran (11, 12). Since that time RSV infection continues to be one of the respiratory tract infection in infants and children which needs to be under consideration. We carried out continuous study of this infection which could represent the degree of occurrence of the disease among the children in Iran.

## Methods

### Specimen

Samples were taken from sick children suffering from respiratory tract infection. The patient were 2 week to four years old. They were suffering from respiratory infection with symptoms of mild fever, cough, coryza and occasional bronchial wheezing. Specimen such as nasal swabs nasopharyngeal wash and laryngeal swabs were taken by experienced medical personnel. They were delivered to Kasra Hospital Laboratory in ice container dish and processed immediately as described previously (11). Briefly, the swabs were washed in 1 ml of PBS and transferred to a centrifuge tube. Auger suction were similarly transferred directly to 1.5 ml microfuge tubes. They were centrifuged 10 min at 2000 rpm. The pellet was suspended in 300  $\mu$ lit of H<sub>2</sub>O to be used for immunofluorescence staining.

### Preparation of the glass slide and specimen coating

Several glass slides were tested for coating the specimen. The two well slides were suitable but relatively large amount of specimen and reagents were required. The six well slides were chosen because several specimen including positive and negative controls could

be tested on the same slide and the wells were small enough to put minimum amount of reagents. The slide were cleaned with acetone, rinsed in distilled water and air dried.

### Immunofluorescence test

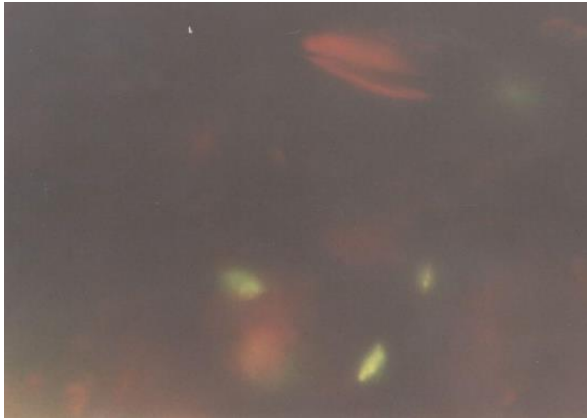
Approximately 30  $\mu$ lit of the suspended centrifuged cells were placed on each slide well. They were allowed to air dry. The cells were fixed with acetone at  $-20^{\circ}\text{C}$  for 10 minutes. Following fixation time the slide were rinsed briefly in PBS and 10  $\mu$ lit of RSV specific monoclonal IgG (Abbot Company .U.S.A) was added to each well and incubated for 1 hr. at  $37^{\circ}\text{C}$ . At the end of incubation time the slides were washed in PBS for 3 minutes and 10  $\mu$ lit of anti IgG conjugated to fluorescein was add and incubated for additional 45 min at  $37^{\circ}\text{C}$ . The slides were washed in PBS as above then mounted with buffered glycerol and examined with a UV equipped microscope. For negative control similar procedures were applied and anti-Rota virus IgG was used.

## Results

From Oct 2012 to April 2014 total of 168 patents suspected of having RSV infection were referred to the hospital .The patients had respiratory signs of illness and fever with occasional cough. Before taking the specimen the history of sickness of each individual was taken and a questioner from regarding the age, sex, and seasonal month was completed. Specimen were processed as described in methods. The prepared specimen were stained using direct IF method and examined by a UV equipped microscope. Duplicate wells of each specimen on the slides were carefully scanned and the cells showing fluorescence were counted. In each specimen containing at least 6 cells with fluorescent antigen were considered positive. The positive cells showed bright intra cytoplasmic fluorescence antigen (Fig. 1).

**Table 1:** RSV positive patients during the winter month in patient referred to Kasra Hospital.

Month	Oct	Nov	Dec	Jan	Feb	Mar	Other month	Total
Patients with respiratory disease	16	28	45	42	24	8	5	168
RSV positive	5	11	24	21	12	3	1	77



**Fig. 1.** Specimens containing respiratory epithelial infected cells were stained as described. Cell showing bright intracytoplasmic immune-fluorescence were positive.

Sometimes the antigens were distributed inside the cytoplasm and appeared as fine fluorescence granules. In this study most of the infection occurred during winter month such as Nov, Dec and Jan. From 168 patients, 111 referred from Dec to Feb and 51 % of them were positive (Table 1). Most of the patients were under one year and the majority were up to 8 month old. However there was one patient, a 36 old woman which was positive indicating that RSV infection can occur in adults (Table 2). There was no significant changes in infection between the males and females.

## Discussion

Respiratory syncytial disease affects infants and young children causing an important respiratory illness (1, 2). Most of the epidemics caused by RSV occurs in children at early age but there are reports of outbreak in people at late stage of life at old age care centers (1, 4). The disease could be very serious and life threatening causing some mortality. In children it usually cause a mild disease which is resolved in a few days. The virus causes fusion of infected cells resulting of syncytial and giant cell formation. Syncytial formation one of the

characteristic of this virus and this phenomena requires calcium. In calcium free medium the viral antigens are synthesized and accumulated in the cytoplasm of infected cells without cell fusion and syncytium formation (13). Glutamine have similar effect on cytopathogenicity of the virus (15). Two strains of RSV have been identified which cause respiratory disease (14) with no significant differences in pathogenicity. Since the virus is very susceptible to environmental conditions and is inactivated easily, therefore, isolation of the virus is not practical in for routine diagnostic test. The rapid reliable method is detection of viral antigens in infected cells of nasopharyngeal specimen. We used this technique and that the disease occurs mainly in cold season and the rate of infection during summer time is very low. Although most of infections were diagnosed during the first six month of age. The was one case of infection in an older person indicating that the infection can occur in adults producing flue like syndromes. However, the results of this study showed that disease is common during the winter time in children Tehran and a rapid reliable such as immunofluorescence should be applied for prompt detection of the disease and its treatment.

## References

1. Glezen WP, Denny FW. Epidemiology of acute lower respiratory disease in children. *N. Engl. J. Med.* 1973;288:498-505.
2. Chanok RM, Roizman B, Myers R. Recovery from infants with respiratory illness of a virus related to chimpanzee coryza agent. Isolation, properties and characterization. *Am. J. Hyg.* 1957;66:281-290.
3. Johnson PR, Collins PL. The fusion glycoproteins of human respiratory syncytial virus of subgroups A and B sequence conservation provides structural basis for antigenic relatedness. *J. Gen. Virol.* 1988;69:2623-8.

**Table 2:** Patients with RSV in different age groups.

Patients age (months)	Number	RSV (+)	RSV(+)%
0-2	42	22	52
2-8	68	24	35
8-16	39	17	43
16-32	18	13	72
Adults(above 20 year)	1	1	100

4. Glezen WP, Taber LH, Frank AL, Kasel JA. Risk of primary infection and reinfection with respiratory syncytial virus. *Am. J. Dis. Child.* 1986;140:543-6.
5. Carbonell-Estrany X, Quero J. The IRIS study group, hospitalization rates for respiratory syncytial virus infections in premature infants born during two consecutive seasons. *Pediatric Infect Dis. J.* 2001;20:874-9.
6. Respiratory syncytial virus. In: Pickering LK, Baker CJ, Long SS, McMillan JA, eds. *Red Book: 2006 report of the Committee on Infectious Diseases*. 27th ed. Elk Grove Village, IL: American Academy of Pediatrics. 2006;560-6.
7. Welliver RC. Review of epidemiology and clinical risk factors for severe respiratory syncytial virus (RSV) infection. *J Pediatr.* 2003;143:S112-7.
8. Cane PA. Molecular epidemiology of respiratory syncytial virus. *Rev Med Virol.* 2001;11:103-16.
9. Nwankwo MU, Dym AM, Schuit KE, Offor E, Omene JA. Seasonal variation in respiratory syncytial virus infections in children in Benin-City, Nigeria. *Trop Geogr Med.* 1988;40:309-13.
10. Stensballe LG, Devasundaram JK, Simoes EA. Respiratory syncytial virus epidemics: the ups and downs of a seasonal virus. *Pediatr Infect Dis J.* 2003;22:S21-32.
11. Shahrabadi MS, Ataei-Pirkooch A. Accuracy of Respiratory Syncytial Virus Infection in Children Referred to Kasra Hospital Diagnostic Laboratory during 2009. *Iranian J of virol.* 2001;5(1):6-9.
12. Milani M. Respiratory Syncytial Virus Infection among Young Children with Acute Respiratory Infection. *Acta Medica Iranica.* 2003;41:4-7.
13. Shahrabadi MS, Lee PWJ. Calcium requirement for syncytium formation in HEp-2 cells by respiratory syncytial virus. *Clin Microbiol.* 1988;26:139-41.
14. Coggins WB, Lefkowitz EJ, Sullender WM. Genetic variability among group A and group B respiratory syncytial viruses in a children's hospital. *J Clin Microbiol.* 1998;36:3552-7.
15. Marquez A, Hsiung GD. Influence of glutamine on multiplication and cytopathic effect of respiratory syncytial virus. *Proc Soc Exp Biol Med.* 1967;124:95-9.