

## Original Article

# Detection of Avian Encephalomyelitis Virus in Broiler Chickens in Iran Using RT-PCR and Histopathological Methods

Ghorani M<sup>1</sup>, Ghalyanchi Langeroudi A<sup>2\*</sup>, Akramian A<sup>3</sup>, Hosseini H<sup>4</sup>, Rohani F<sup>5</sup>

1. Pathobiology Department, Faculty of Veterinary Medicine, University of Tabriz, Tabriz, Iran.
2. Microbiology and Immunology Department, Faculty of Veterinary Medicine, University of Tehran, Tehran, Iran.
3. Veterinary Laboratory, Kashan, Iran.
4. Clinical Sciences Department, Faculty of Veterinary Medicine, Islamic Azad University, Karaj Branch, Karaj, Iran.
5. Isfahan Veterinary Office, Isfahan, Iran.

## Abstract

**Introduction:** Avian encephalomyelitis is caused by a Tremovirus and primarily affects chickens. The virus can infect young chicks and cause nervous symptoms. Vaccines are used to control the disease in breeders. Recently, the occurrence of the disease is causing concern in the poultry industry.

**Materials and Methods:** In the present study, we report a case of avian encephalomyelitis in one broiler farm in Kashan (center of Iran). The chickens showed nervous symptoms like depression, head trembling, ataxia, dull eyes, as well as drowsiness, lack of coordination, and unsteady gait in chickens. In this study, we detected avian encephalomyelitis with the molecular procedure like reverse transcriptase-polymerase chain reaction (RT-PCR). Also, the histopathological diagnosis was made.

**Results:** The disease was confirmed based on the clinical, molecular and histopathological findings.

**Conclusions:** Due to the increase in vaccine prices and the difficulties of vaccine providing in the breeders' farms, the probability of disease has increased. Stringently monitoring of breeders farms before the beginning of egg production and using a suitable protocol with vaccination is recommended.

**Keywords:** avian encephalomyelitis, broiler, RT-PCR, histopathology, Iran

## Introduction

Avian encephalomyelitis (AE) is a virus-born disease primarily infecting poultry. The disease imposes a significant financial burden on related industrial companies annually. AE virus (also known as tremovirus A) belongs to the

picornaviridae family, Tremovirus genus (1, 2). AE was initially recognized in the United States in the early 19th century; however, the disease is now widespread across the world. The AE resembles human poliomyelitis and swine polioencephalomyelitis regarding pathological features. This condition affects 1-21-day old but not older chickens. Although antigenic types are unique, virulence factors of the AE virus differ considerably. When first infecting a flock, AE inflicts a high mortality rate in young poultry; nevertheless, the death toll can be reduced by vaccinating young birds. However, some evidence suggests that even vaccination may not be highly efficient is preventing the rising incidence of AE (3). The fecal-oral route is the main way of propagation

\* **Corresponding author:** Corresponding Author: Arash Ghalyanchi Langeroudi  
Microbiology and Immunology Department,  
Faculty of Veterinary Medicine, University of Tehran,  
Qareeb Street, Azadi Av.,  
P.O.Box : 14155-6453, Tehran - Iran.  
Telephone: +982161117154  
E-mail: arashghalyanchi@gmail.com

## Detection of Avian Encephalomyelitis Virus in Broiler Chickens in Iran Using RT-PCR and Histopathological Methods

of the AE virus, but transmission can also be facilitated by eggs of infected animals. Infected eggs are susceptible to loss of hatch.

As maternal antibodies can effectively protect chickens during 21 days after hatching, the incidence of the AE infection is greatly reduced following its initial establishment (1).

After a window period of either 17 or 11 days (based on the type of transmission; i.e., vertical or horizontal respectively), the disease presents with symptoms such as dullness, progressive ataxia, head and neck tremors, weight loss, blindness, paralysis, and even prostration, coma, and death. Even recovered poultry will suffer from deterioration of the central nervous system (CNS).

Seronegative animals may show reduced egg production as high as 50% without any clinical symptoms (1). In an outbreak infecting around 60,000 birds in Shiraz, Iran, the mortality rate was reported as 5% (2).

The AE infection can be diagnosed with suggestive clinical and histopathological features and confirmed by immunofluorescence staining. The diagnosis can be assisted by culturing or inoculating the virus through the yolk sac in eggs of 5-7 day-old from embryonated antibody free hens and screening the signs of AE in hatched chicks for 7 days. The disease can also be diagnosed by RT-PCR, serological tests, and ELISA, which the recent strategy using purified or recombinant antigens is becoming the gold standard. It is important to differentiate AE from similar diseases such as Newcastle disease, as well as from non-viral causes of CNS involvement (1).

AE can be managed by either depopulation or vaccination of infected poultry. Vaccines comprising attenuated viruses can be fed to animals through the drinking water at around 8-week of age. The vaccines are supposed to protect chicken at the first 21 days after hatching and should be administered at least 4 weeks before the onset of egg-laying. This is ensured by achieving a protective level of antiviral antibodies in chickens. As the viruses may not be sufficiently attenuated, direct vaccination of chickens is discouraged; besides, this strategy generally fails to confer timely protection to chicks hatched in a

contaminated environment. Accordingly, a study in Brazil reported an increasing incidence of AE despite vaccination highlighting the importance of timely vaccination (3).

Inactivated vaccines, which can be administered to quail and turkey as well, maybe used to protect immunized birds housed next to nonimmunized chickens (1). In a recent study in Japan, the presence of AEV confirmed via sequence analysis (4).

In this study, we announced the occurrence of AE in a broiler farm in Kashan. The molecular detection and histopathological studies were performed.

### Materials and Methods

**Case History** Overall, 50,000 birds (2-day-old) suspected to have AE infection were gathered from commercial broiler flocks of Kashan (Isfahan, Iran). Clinical symptoms of AE were observed in around 20% of the birds, and the overall mortality rate was about 5%. Samples from the brain, proventriculus, and pancreas were obtained from dead birds. The specimens were divided into two parts; one part for molecular study and another fixed in 10% buffered neutral formalin for pathological studies, as reported by Ono et al. (5). The Newcastle disease (ND) was excluded in all the birds because the hemagglutination inhibition (HI) test of ND did not show the presence of the disease at different times that blood was taken from the chicks.

The clinical signs included depression, head trembling, lateral recumbency (being one side-down), ataxia, dull eyes, as well as drowsiness, lack of coordination, and unsteady gait in chickens.

**RT-PCR** RNA extraction and cDNA synthesis were performed using specific kits (Sinaclon, Iran) according to the manufacturer's protocols. The primers used in this study have been shown in Table 1. In this research, we used the MK AE primers (Table 1). These primers detect the VP2 gene (structural protein) of the virus.

The viral RNA was isolated by the SinaPure ONE kit (SinaClon Co., Iran) from the supernatants as recommended by the

manufacturer. The cDNA was synthesized using the Thermo Scientific reverse transcriptase PCR (RT-PCR) kit using a random hexamer (Thermo Scientific, USA). For the PCR reaction, 2.5 µl cDNA, 12.5 µl of master mix (Sinaclon Co., Iran), 1 µl of each primer, and 3 µl of sterile DEPC-treated distilled water (totally 20 µl) were added. The reaction mixture was denatured at 95° C for 5 min. Then the PCR was run for 35 cycles at 94° C for 1 min with annealing and extension temperature and time of 62° C and 1 min, respectively; the sample was then incubated at 62° C for 10 min for one cycle, with the final extension at 4° C. A PCR method described by Xie *et al.* (6) was used to amplify a 619 bp product of VP2 gene.

The PCR products were electrophoresed on a 1 % agarose gel, stained with safe stain (Sinaclon Co., Iran), and were detected under UV light.

## Results

All the samples were positive for AE in PCR analysis.

Microscopically, there were obvious dense pathognomonic nodules of lymphocytic muscular aggregations in the proventriculus wall (figure 1A).

Moreover, increased circumscribed lymphocytic follicles and vascular congestion were observed in the pancreas (figure 1B).

Furthermore, focal hemorrhage, perivascular and perineuronal edema, prominent lymphocytic perivascular cuffing, diffuse microgliosis, and central chromatolysis were found in the brain sections (figure 1C, D).

## Discussion

Strong clinical and histopathological evidence such as lymphocytic perivascular infiltration,

gliosis, as well as CNS neuronal degradation associated with lymphoid follicles hyperplasia in the proventriculus and pancreas can be used as reliable features to diagnose AE in poultry timely. In particular, histologic lesions were evident in all the birds with clinical signs of AE in the present study.

AE should be differentiated from other similar avian diseases such as Newcastle disease, nutritional encephalomalacia (e.g., vitamin B and E deficiencies), and Marek's disease (7).

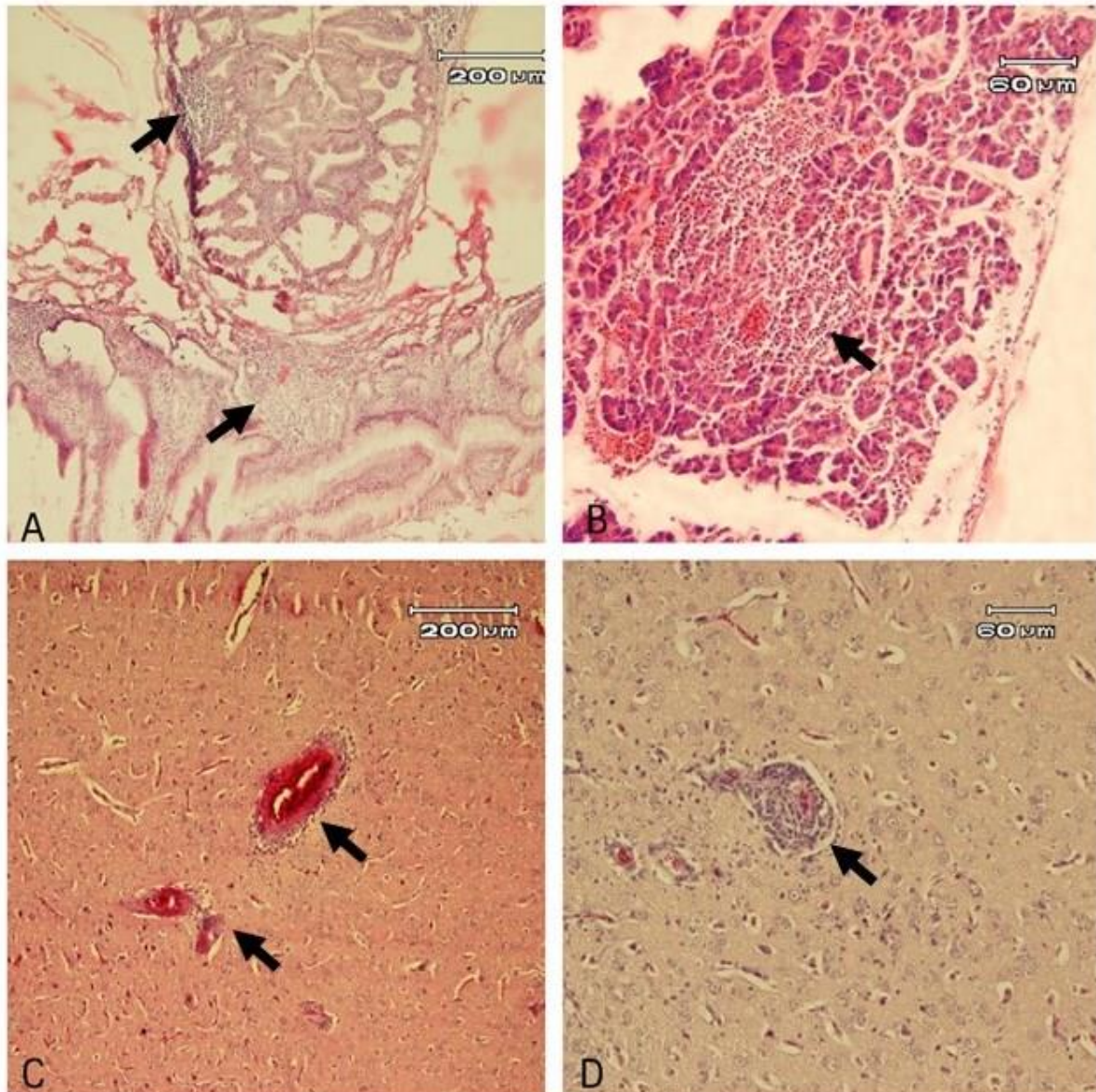
Both AE and Newcastle disease primarily affects 1- to 3-week-old chickens. However, certain histological lesions in the CNS and visceral organs, including lymphocytic hyperplasia in the proventriculus muscular wall and circumscribed lymphocytic follicles in the pancreas, can help to differentiate AE from the Newcastle disease. On the other hand, there is a prominently higher mortality rate in Newcastle disease which is commonly accompanied by severe proventriculus and intestinal hemorrhage. Nutritional encephalomalacia usually occurs with a 2–to 3-week latency period after AE, and it can be readily differentiated by clinical history the signs (e.g., severe degenerative lesions and particularly leukoencephalomalacia which is not observed in AE). In Marek's disease which occurs in older chickens, the peripheral nerve involvement (particularly in the sciatic nerve) and lymphomatosis of the viscera are two main criteria that are not features of AE (7).

AE virus can be transmitted through either vertical (i.e., eggs from hens with subclinical infection) or horizontal (i.e., direct contact with infected poultry) routes. Although hatchability is reduced in infected hens, their eggs will produce chickens with clinical AE which can further propagate the infection through shedding the virus in feces (8, 9).

**Table 1.** Primers using for AE detection

Primer name	Primer sequence (5' to 3')	Length of amplified product	Gene	Reference
MK AE1	CTTATGCTGGCCCTGATCGT	619-base pair (bp)	VP2	(10)
MK AE2	TCCCAAATCCACAAACCTAGCC			

## Detection of Avian Encephalomyelitis Virus in Broiler Chickens in Iran Using RT-PCR and Histopathological Methods



**Figure 1.** Broiler chicken, avian encephalomyelitis. A: obvious dense nodules of lymphocytic aggregations within the muscular wall of the proventriculus (arrows). B: hyperplasia of lymphocytic follicles in the pancreas. C, D: diffuse gliosis associated with prominent lymphocytic perivascular cuffing in the brain. H&E.

### Conclusion

As regards that the price of vaccines is increasing continually, some of the breeders' farms do not use the high quality vaccine. On the other hand, the difficulties of vaccine providing for breeders' farms increases the probability of disease incidence. Stringently monitoring of breeders farms before the beginning of egg production and using a

suitable protocol with vaccination is recommended.

### References

1. Maclachlan N, Dubovi E. Adenoviridae. Fenner's veterinary virology, 5th Ed. Academic Press San Diego, California; 2016.
2. Asasi K, Farzinpour A, Tafti AK. Clinico-pathological studies on avian encephalomyelitis in Shiraz, Iran. Turk J Vet Anim Sci. 2008;32(3):229-31.

3. Back A. New Occurance of Avian Encephalomyelitis in Broiler-Is this an Emerging Disease? *Braz J Poult Sci.* 2015;17(3):399-404.
4. Goto Y, Yaegashi G, Kumagai Y, Ogasawara F, Goto M, Mase M. Detection of avian encephalomyelitis virus in chickens in Japan using RT-PCR. *J Vet Med Sci.* 2019;81(1):103-6.
5. Ono M, Okuda Y, Yazawa S, Imai Y, Shibata I, Sato S, et al. Adenoviral gizzard erosion in comercial broiler chickens. *Vet Pathol.* 2003;40(3):294-303.
6. Xie Z, Khan MI, Girshick T, Xie Z. Reverse transcriptase-polymerase chain reaction to detect avian encephalomyelitis virus. *Avian Dis.* 2005;49(2):227-30.
7. Suarez LD. Avian Encephalomyelitis In: *Diseases of Poultry*, edited by David E. Swayne, 13th edition. 2013:486-94.
8. Epidemic Tremor, In *Merck Veterinary Manual*, National Publishing Inc. Eight ed. 1998:p 1971.
9. Office International des Epizooties. 2002.
10. Marvil P, Knowles NJ, Mockett A, Britton P, Brown T, Cavanagh D. Avian encephalomyelitis virus is a picornavirus and is most closely related to hepatitis A virus. *J Gen Virol.* 1999;80(3):653-62.