

## Original Article

# Atypical Fowl Pox in Silkie, Iran, 2021

Zamani T<sup>1</sup>, Montazeri M<sup>1</sup>, Hosseini H<sup>2</sup>, Ghalyanchilangroudi<sup>3,\*</sup>, Ziafati Kafi Z<sup>3</sup>, Sadri N<sup>3</sup>, Hojabr Rajeoni A<sup>3</sup>

1. Department of Avian Medicine, Faculty of Veterinary Medicine, University of Tehran, Tehran, Iran

2. Department of Clinical Sciences, Faculty of Veterinary Medicine, Karaj Branch, Islamic Azad University, Alborz, Iran

3. Department of Microbiology and Immunology, Faculty of Veterinary Medicine, University of Tehran, Tehran, Iran

### Abstract

Avian pox infection is a widespread disease with cyclical occurrence in endemic areas, especially with dense poultry production. An unusual fowl pox outbreak was diagnosed in 18 weeks old vaccinated Silkie herd during autumn 2021 in Qom province, Iran. The most characteristic observation of this outbreak was that the pox signs and lesions were observed on the feathered parts of the body. No Classical pox lesions were observed in the mouth, eyelids, and shank. The objective of this study was to report the occurrence of fowl pox in Silkie for the first time and describe clinical and molecular features of a case of atypical fowl pox, and to realize if a new isolate has been emerged. The sample was collected from cutaneous lesions for molecular virus detection. Detected viruses were genetically similar to previous FP viruses.

**Keywords:** Atypical; fowl pox; Phylogenetic analysis; vaccine; PCR; Silkie; Iran

### Introduction

Pox is one of the earliest known and common slow-spreading diseases of birds caused by a DNA virus of the *Avipoxvirus* genus, *Poxviridae* family, and is widely distributed throughout the world [1, 2]. Infection with Pox virus occurs in chickens [2], turkeys [3], canaries [4], pigeons [5] and etc. The disease occurs in many clinical forms; the cutaneous form, which is usually mild, is characterized by the appearance of nodular lesions on the comb, wattle, eyelids, and other non-feathered areas of the body. Cutaneous eye lesions interfere with the bird's ability to find food and water. In the diphtheritic form, cankers or diphtheritic yellowish lesions occur on the mucous membranes of the mouth, esophagus, or trachea with accompanying coryza-like mild or severe respiratory signs similar to those caused by infectious laryngo-

tracheitis virus infection of the trachea [2].

### Case History

A multiage (immature to 2 years old) breeder Silkie flock at Qom province with a history of cutaneous lesions and 10% mortality and 60% morbidity were examined during autumn 2021. Clinical lesions were only observed at the age of 4 months and older. The flock was raised on a free-range system and vaccinated for fowl pox. Affected birds strongly refused mating due to scarring in the posterior dorsal area.

### Methods

**Virus isolation and DNA extraction:** Samples from skin lesions were transferred to Veterinary Medicine's microbiology and immunology laboratory, University of Tehran. DNA was extracted by the SinPure DNA extraction kit (Sinaclon, Iran). A lyophilized live fowl pox vaccine (Razi Vaccine And Serum Research Institute, Iran) was a positive

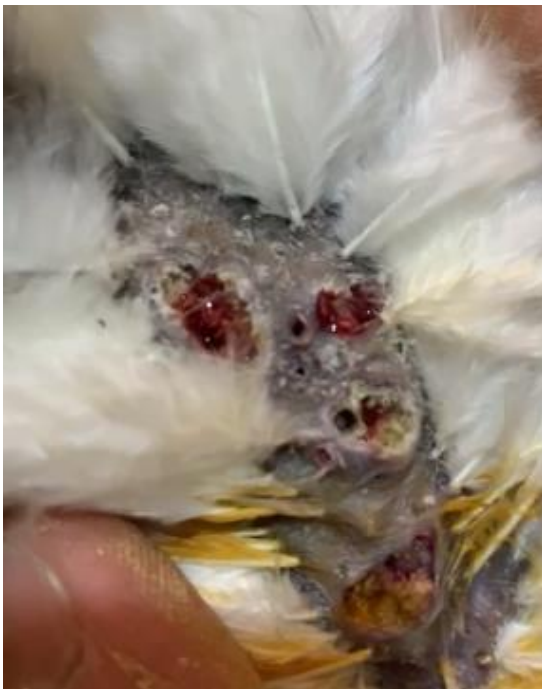\* **Corresponding author:**  
Arash Ghalyanchi Langeroudi.  
Email: ghalyana@ut.ac.ir.

control. Extraction was performed based on the manufacturer's recommendations.

**PCR:** APV-specific PCR was conducted using primers as described by Lee and Lee (1997) [6] (P1:5' CAGCAGGTGCTAAACAACAA-3'; P2: 5'-CGGTAGCTTAACGCCGAATA-3') and based on APV P4b gene sequence [7].

These primers amplify a fragment of about 578 bp. PCR Master Mix 2x (Sinaclon, Iran) were used, 6 pmol of each primer, 60 ng DNA sample, and nuclease-free water up to 25 µl were added .

**PCR parameters for amplification:** initial DNA denaturation over 2 min at 94 °C followed by 35 cycles of 1 min denaturation at 94°C, 1 min annealing at 60°C, and 1 min elongation at 72°C and terminated with a final extension step at 72 °C for 2 min [8].

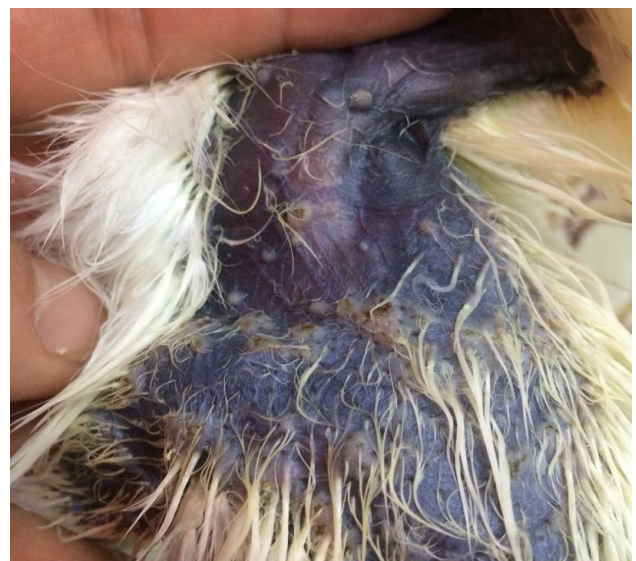

**Fig 1.** Pox lesions in the posterior dorsal area of a nine month old Silkie hen.

**DNA sequencing and analysis:** PCR products were sent for sequencing (Bioneer Co., Korea) with PCR primers for forward and reversed directions. The sequence results were downloaded and analyzed using Chromas (Technelysium Pty Ltd., Australia).

Phylogenetic analysis was performed by analyzing the obtained data and comparing it to those of other FPVs sequences. DNA sequencing was carried out for 25 strains.

An automatic sequencer (ABI-370, Applied Biosystem) and both forward and reverse primers were sequencing. Sequences were selected from isolates of countries as near as possible based on different places and times of reporting. Sequence analysis was performed by the neighbor-joining method (Tamura-Nei model) with the MEGA7 program. The robustness of the phylogenetic trees was assessed by 1,000 bootstrap replicates with values higher than 50. The FPV sequences tested in this study were deposited in GenBank under accession numbers POX 2021 UT-Vasfi.



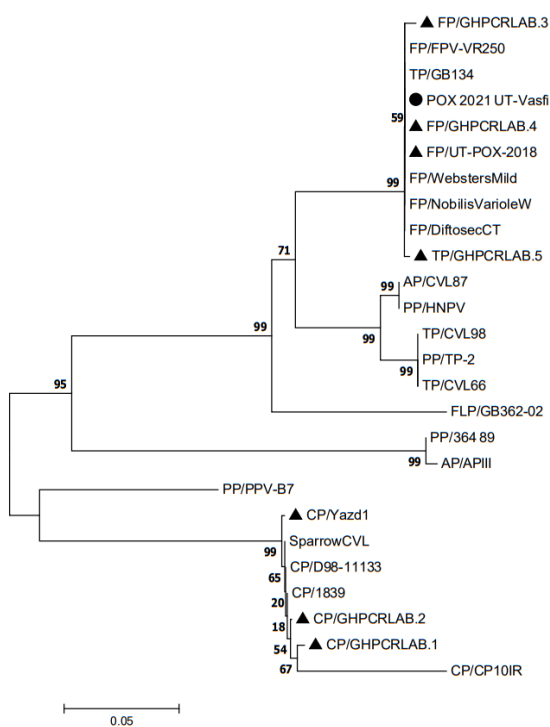
**Fig 2.** Pox lesions in the feathered area of a 9-month-old Silkie rooster.

## Results

**Molecular detection:** The detected APV specific DNAs in samples belonged to the genus Avipoxvirus of the family Poxviridae. In addition, the obtained amplified fragments of approximately 578 bp for the P4b gene were noticed to be consistent with the size of 578 bp based on the published APV P4b nucleotide sequence .

**Sequence analysis:** The amplified region of the P4b gene was sequenced for one isolate, and as depicted in table 1, the nucleotide sequence similarity to 10 selected sequences of APV strains in the GenBank showed a similarity of 99.17-99.80%. The generated phylogenetic tree and identity matrix showed four distinguishable sequence clusters. The

strain of the present study belonged to the first cluster, which has four strains from Iranian commercial laying herds and several strains from different countries and birds (Fig. 3). The Iranian avipoxvirus isolates in this study grouped in clade A1 with other Iranian commercial chicken avipoxviruses. Sequencing of the partial fpv167 gene coding for the P4b core protein of Avipox and sequence alignment revealed 99.79% similarity to the FP/NobilisVarioleW (vaccine) and 99.77 similarities to the fowlpox virus vaccine strain (FPV-VR250).



**Fig 3.** Phylogenetic tree of the nucleotide sequence of the 4b core protein gene PCR fragment of different APVs tested and the published sequence in GenBank was constructed by the neighbor-joining method with the MEGA7 program. The name of the origin country of each isolate has been added to the end of its name in the tree. Values at the branches and clusters are bootstrap values, and the bar indicates the distance scale from the roots.

## Discussion

Typical cutaneous fowl pox usually occurs at injured, featherless skin areas of the head, legs, feet, and toes. The poxvirus infects those areas when it is mechanically transmitted [2]. The

typical distribution of cutaneous fowl pox and the encrusted proliferative type of skin lesion are important characteristics for clinical diagnosis. In this case, although the lesions had a proliferative appearance, the distribution of the lesions in feathered areas of the skin and the complete absence of lesions on the featherless areas of the head were not consistent with typical cutaneous fowl pox.

It is known that several species of mosquitoes can serve as vectors for fowl poxvirus [2]. The involvement of mosquitoes in this outbreak was considered unlikely, as they are not common in this region of Iran during autumn. The distribution of the lesions is also not typical for mosquito-transmitted pox.

*Dermanyssus gallinae* has been reported to transmit fowl poxvirus [9]; however, mites were not found on the facility after searching the crevices and cracks. Moreover, pox lesions were not seen at the cloacal openings, a common area for mite infestation.

A similar atypical fowl pox was reported from broilers [1, 10]. To the authors' knowledge, this is the first time that cutaneous fowl pox, occurring only in feathered areas of the skin, has been reported from Silkie in Iran.

The genomes of APVs are extremely conserved [11, 12], and because of containing two-stranded DNA, the rate of mutation is relatively low in Poxviridae [13]. The P4b is a conserved region of the fowlpox genome, which is less likely to undergo frequent mutation, and this may explain the high degree of homology observed in the clustering on the phylogenetic tree. Our study also corroborates similar observations by Carulei *et al.* (2009) [11] and Murphy *et al.* (1999) [13], suggesting that the PCR amplification of the P4b gene is a valuable diagnostic method for fowlpox infection. The conventional diagnosis of APVs is based on histopathological examination, electron microscopy, virus isolation on chorio-allantoic membrane (CAM) of embryonated chicken eggs or cell-cultured, and serological methods [14].

The techniques above are usually complex, and it takes longer to perform them [15, 16], but PCR is a reliable method and easier than other procedures for detecting APVs.

**Table 1.** Percentage of 4b core protein sequence identity of APV isolated in this study and some selected APV isolates from GenBank

		1	2	3	4	5	6	7	8	9	10
1	POX2021 UT-Vasfi										
2	FP/GHPCRLAB.4	99.80									
3	FP/UT-POX-2018	99.80	100.00								
4	TP/GB134	99.80	100.00	100.00							
5	FP/WebsterMild	99.80	100.00	100.00	100.00						
6	FP/NobilisVarioleW	99.79	100.00	100.00	100.00	100.00					
7	FP/FPV-VR250	99.77	100.00	100.00	100.00	100.00	100.00				
8	TP/GHPCRLAB.5	99.59	99.79	99.79	99.79	99.79	99.79	99.77			
9	FP/DiftosecCT	99.59	99.79	99.79	99.79	99.79	99.79	100.00	99.79		
10	FP/GHPCRLAB.3	99.17	99.38	99.38	99.38	99.38	99.38	99.53	99.38	99.38	

In the recent study by Ghalyanchi et al. (2012), APVs on clinical cases of affected commercial chickens, turkeys, and canary were identified and characterized by molecular methods to determine the etiology of APV in Iran [17].

Another research was done by Gholami-Ahangaran et al. (2014) on avian pox of backyard poultry in Iran. They indicated that 66.1% and 80.7% of samples were positive for the virus using histopathological and PCR methods, respectively [18].

Avian pox infection is a disease with cyclical occurrence in endemic areas, especially in areas with dense poultry production [2]. Some factors may be relevant in identifying the source of an outbreak; for example, it occurs in a limited number of birds, with high morbidity but less mortality. Aligning the sequences of the avipoxvirus gene, we demonstrated that the virus does not stem from wild birds or passerines [19].

This research is the first report of the APVs outbreak in a commercial Silkie herd in Iran. The current study attempted to realize if a new isolate has been emerged and, if so, what the difference is and how it has appeared. In this study, the isolate shared 99.17-99.80% homology with the selected sequences from GenBank and clustered on the phylogenetic tree in clade A, subclade A1 with other strains

from Iranian commercial herds fowlpox virus (Fig. 3).

Genomic and antigenic variation in circulating field and vaccine strains could lower vaccine efficacy requiring close monitoring, especially where outbreaks in vaccinated flocks are observed, as reported by Nie et al. (2000) [20] and Odoya et al. (2006) [21].

Fowlpox (FP) vaccine is used in the Iranian poultry industry in layer and breeder farms, although specific live avian pox vaccines have yielded better commercial poultry farms. Most FP vaccine manufacturers search for new vaccine candidates as the routine ones may not prove up to the mark. One of the possible alternatives may be evaluating FP isolates from a vaccinated flock with this aspect. However, the problem of contamination with other interacting viral pathogens is yet to be solved.

Therefore, the search for suitable APV as a candidate vaccine strain could be attempted as it has less possibility of contamination but induces full immunogenicity [22]. The literature also reveals reports on fowlpox vaccination failure. Thus the need for efficient and improved vaccines is being felt. It seems indispensable to investigate vaccines' efficacy, which is used in Iranian commercial laying herds routinely to illuminate whether these vaccines have appropriate efficacy or not and they are still effective?

Furthermore, we intended to update the viral monitoring system as to country livestock and poultry. Finally, the phylogenetic tree was generated to increase the relationship between this virus and the other strains isolated from other regions in GenBank. In this study, there were 4 clusters, and phylogenetic analysis showed that the strain of our study (Iranian strain) belonged to the first cluster with 99.17-99.80% identity to the other members of this group.

## Conclusions

It means our strain in atypical FP, has not changed as compared to the previous strain isolated from Iran.

## Acknowledgment

The authors would like to thank the Ghalyanchi lab experts ( University of Tehran) for their extensive technical supports.

## Conflict of interest

No conflict of interest is declared.

## Funding

This research received no specific grant from any institution.

## References

1. Sentfies-Cué CG, Charlton B, Woolcock P, Bickford A, Cooper G, Bland M. Atypical distribution of fowl pox lesions in broilers. *Avian Dis.* 2010;54(4):1316-8.
2. Tripathy DN, Reed WM. Pox. In Swayne DE, Boulianne M, Logue CM, McDougald LR, Nair V, Suarez DL, editor: *Diseases of poultry*. Vol 14. New York; JohnWiley & Sons; 2020. p.364-81.
3. Forrester D. The ecology and epizootiology of avian pox and malarla in wild turkeys. *Bull SoC Vector Ecol.* 16(1);127-148 .
4. Johnson B, Castro A. Canary pox causing high mortality in an aviary. *J Am Vet Med Assoc.* 1986;189(10):1345-7.
5. Abd El Hafez M, Shosha E-M, Ibrahim S. Isolation and molecular detection of pigeon pox virus in Assiut and New Valley Governorates. *J Virol Methods.* 2021; 114142.
6. Lee LH, Lee KH. Application of the polymerase chain reaction for the diagnosis of fowl poxvirus infection. *J Virol Methods.* 1997;63(1-2):113-9.
7. Binns M, Bournell M, Tomley F, Campbell J. Analysis of the fowlpoxvirus gene encoding the 4b core polypeptide and demonstration that it possesses efficient promoter sequences. *Virology.* 1989;170(1):288-91.
8. Manarolla G, Pisoni G, Sironi G, Rampin T. Molecular biological characterization of avian poxvirus strains isolated from different avian species. *Vet Microbiol.* 2010;140(1-2):1-8.
9. Shirinov F, Ibragimova A, Misirov Z. Spread of fowl pox virus by the mite *Dermanyssus gallinae*. *Veterinariya (Moscow).* 1972(4):48-9.
10. Fallavena L, Rodrigues N, Scheufler W, Martins N, Braga A, Salle C, et al. Atypical fowlpox in broiler chickens in southern Brazil. *Vet Rec.* 1993;132(25):635.
11. Carulei O, Douglass N, Williamson A-L. Phylogenetic analysis of three genes of Penguinpox virus corresponding to Vaccinia virus G8R (VLTF-1), A3L (P4b) and H3L reveals that it is most closely related to Turkeypox virus, Ostrichpox virus and Pigeonpox virus. *Virol J.* 2009;6(1):1-5.
12. Schnitzlin W, Ghildyal N, Tripathy D. Genomic and antigenic characterization of avipoxviruses. *Virus Res.* 1988;10(1):65-75.
13. Murphy FA, Gibbs EPJ, Horzinek MC, Studdert MJ: *Veterinary virology*. 3th ed. Cambridge, MA, Academic Press, 1999.
14. Tadese T, Fitzgerald S, Reed WM. Detection and differentiation of re-emerging fowlpox virus (FWPV) strains carrying integrated reticuloendotheliosis virus (FWPV-REV) by real-time PCR. *Vet Microbiol.* 2008; 127(1-2):39-49.
15. Joshi R, Shakya S. Rapid diagnosis of fowl pox with coagglutination assay. *Trop Anim Health Prod.* 1997;29(3):147-50.
16. Prukner-Radovčić E, Lüscho D, Grozdanić IC, Tišljarić M, Mazija H, Vranešić L, et al. Isolation and molecular biological investigations of avian poxviruses from chickens, a turkey, and a pigeon in Croatia. *Avian Dis.* 2006;50(3):440-4.
17. Ghalyanchilangeroudi A, Hosseini H, Morshed R. Molecular characterization and phylogenetic analysis of avian pox virus isolated from pet birds and commercial flocks, in Iran. *Slov Vet Res.* 2018;55(4):213-8.
18. Gholami-Ahangaran M, Zia-Jahromi N, Namjoo A. Molecular detection of avian pox virus from nodular skin and mucosal fibrinonecrotic lesions of Iranian backyard poultry. *Trop Anim Health Prod.* 2014;46(2): 349-53.
19. Ferreira BC, Ecco R, Couto RM, Coelho HE, Rossi DA, Beletti ME, et al. Outbreak of cutaneous form of avian poxvirus disease in previously pox-vaccinated commercial turkeys. *Pesqui Vet Bras.* 2018;38(3):417-24.
20. Nie X, Singh RP. Detection of multiple potato viruses using an oligo (dT) as a common cDNA primer in multiplex RT-PCR. *J Virol Methods.* 2000;86(2):179-85.

## Atypical Fowl Pox in Silkie, Iran, 2021

21. Odoya E, Abegunde A, Agyogbo B, Omatainse S, Gwankat E, Okpara U. Outbreak of turkey pox disease in fowl pox vaccinated poults in Vom Plateau State of Nigeria. *African J Clin Exp Microbiol.* 2006;7(2):136-8.
22. Khan FF. Studies on field strain of pigeon pox virus and its comparison with field and vaccine strains of fowl pox virus (Doctoral thesis, Submitted to Chhattisgarh Kamdhenu Vishwavidyalaya, Durg). 2014.