

EVALUATION OF THE PATHOGENICITY OF A/CHICKEN/IRAN/ZMT-173/99(H9N2) STRAIN OF AVIAN INFLUENZA VIRUS IN SEROLOGICALLY MYCOPLASMA GALISEPTICUM POSITIVE AND NEGATIVE BROILER CHICKENS

Mehdi Vasfi Marandi^{1*}, Jafar Pazani¹, Ashrafi Helan², Seyed Houssein Marjan Mehr² and Farid Ghods³

¹ Poultry Diseases Section, Department of Clinical Sciences, Faculty of Veterinary Medicine, University of Tehran, Tehran-Iran.

² Department of Pathology, Faculty of Veterinary Medicine, University of Tehran, Tehran - Iran.

³ Veterinary Organization of Iran, Tehran-Iran

Abstract: Avian influenza (AI) is the most important poultry diseases in Iran. The objective of this study was the evaluation of the Intravenous Pathogenicity Index (IVPI) of A/Chicken/Tehran/ZMT-173/99(H9N2) strain, isolated from the kidney of the broiler chickens with 40% mortality. Two groups of chickens with Myco plasma Galisepticum (Mg) positive and negative (Mg + and Mg-) status were inoculated via intravenous (IV) rout, and two other similar groups, were inoculated through both IV and oculonasal (ON) routs with $10^{7.5}$ ELD₅₀. The pathogenicity index of the virus in all groups was below 1, indicating the low pathogenesis of H9N2 strain for chickens. The great difference between pathogenesis of H9N2 strain in Mg + and Mg- groups, were 10 percent mortality in each Mg + groups. Formation of casts in tracheal bifurcation was observed only in chickens inoculated via IV along with ON routs and died at 5th day PID. This observation suggests that simultaneous inoculation of chickens play an important role in formation of tracheal casts. Kidney and lymphoid tissues including thymus and bursa of fabricious were more severely affected in the chickens that were inoculated via IV rout alone and died at 7th day PID. Demonstration of H9N2 tropism to lymphoid organs indicates a probable immunosuppressive effect of H9N2 strain for chickens. Based on the results obtained, it is suggested that tracheal casts and severe nephritis with urate deposition are the principal cause of mortality in commercial Mg + chickens. Eventual immunosuppression of chickens due to H9N2 infection as well as bacterial co-infection such as *M. gallisepticum* and *E. coli* might have increased the pathogenesis of H9N2 infection.

Keywords: • Avian influenza • H9N2 subtype • pathogenesis • broiler chickens

Introduction

Influenza viruses belong to the family *Orthomyxoviridae* and genus *influenza virus*. These viruses are classified into three types A, B and C, on the basis of their internal nucleoprotein and matrix protein antigens. Both

antigens are regarded as common to all strain of the same type. Influenza viruses are further categorized into subtypes, according to their surface hemagglutinin (H) and neuraminidase (N) glycoproteins. Avian influenza viruses (AIVs) belong to type A, and 16 H subtypes (H1-H16) and 9 N subtypes (N1-N9) have been reported [2, 32]. Based on the pathogenesis of AIVs to domestic poultry, these viruses are sub-classified into two pathotypes of highly pathogenic avian influenza (HPAI) viruses, causing rapid mortality in poultry, which often approaches 100 % and non-highly

* Corresponding author: Mehdi Vasfi Marandi, Poultry Diseases Section, Department of Clinical Sciences, Faculty of Veterinary Medicine, University of Tehran, Tehran-Iran.
P.O.Box :14155-6453, Tel : 0098-9123844432, Fax : 0098-66933222, E. mail: mvmarand@ut.ac.ir

pathogenic avian influenza (nHPAI) viruses including mildly pathogenic (MP), low pathogenic (LP) and non pathogenic (NP) AIVs, causing subclinical diseases with mild respiratory signs and egg production losses, however, sometimes with slightly elevated mortality. A concomitant infection with other viral or bacterial agents could cause exacerbation of this influenza infection resulting in, severe disease with high mortality rate, although the viruses isolated in these cases still produce little or no disease in experimentally infected chickens [2, 10, 25]. To date, all HPAI isolates have been of H5 and H7 subtypes, although viruses of these subtypes do not necessarily cause HPAI. These viruses are listed as group A diseases by the Office International des Epizooties (OIE) [4, 26].

Avian influenza disease due to H9N2 subtype in poultry during later part of the 1990s has been noticeably increased worldwide. The H9N2 subtype outbreaks occurred in domestic ducks, chickens and turkeys in Germany during 1995 and 1998; chickens in Italy during 1994 and 1996; pheasants in Ireland during 1997; ostriches in South Africa during 1995; turkeys in USA during 1995 and 1996; and chickens in Korea and China during 1996-2006. More recently, H9N2 viruses have been reported in Middle Eastern countries and have been responsible for widespread and serious disease problems in commercial chickens in Iran, Pakistan, United Arab Emirates, occupied Palestine (Israel) and Saudi Arabia [1,6,7,12,15, 17,19].

Avian influenza due to H9N2 subtype has occurred in densely populated area of Tehran province of Iran and caused serious economic losses in poultry industry in 1998 [20, 28, 31]. Since these highly contagious viruses were spread in breeder flocks of other provinces of country [29], a vaccination strategy by using inactivated H9N2 vaccine was adopted to control AI disease in poultry industry [30]. However, some outbreaks continued to occur in several broiler and layer flocks with great economic losses. Banani *et al.*, (2002) and Nili and Assasi (2003) proposed that the secondary bacterial infections such as *Ornithobacterium rhinotracheal*, *Escherichia coli* and *Mycoplasma galisepticum* (Mg) may play an important role in increasing the pathogenesis of H9N2 infection in chickens [5,18] by producing bacterial proteases which enhances the, cleavage of HA glycoproteins [8,21]. All H9N2 subtype viruses isolated from vaccinated or unvaccinated chickens belonged to

nHPAI upto now. However, increasing mortality due to formation of fibrinous casts in tracheal bifurcation and sever urate deposition in some broiler flocks infected with H9N2 subtype pose a question about its pathogenesis. Asphyxiation of chickens resulting from bronchial casts has not been previously reported in experimental infection both in SPF and commercial chickens. This study was designed to investigate the pathogenic potential of a H9N2 strain in Mg positive and negative commercially- produced chickens.

Material and Methods

Viruse and chickens

A/Chicken/Tehran/ZMT-173/99 (H9N2) isolated from the kidney of broiler chicken flocks, with 40% mortality was used in this study. This virus was propagated in 10-day-old embryonated chicken eggs using standard procedure [22]. Amnio allantoic fluid (AAF) was harvested and used as inoculate to determine the pathogenesis of the virus for chickens. The Ross broiler chickens obtained from two different Mg⁺ and Mg⁻ commercial broiler breeders vaccinated against H9N2, were reared up to 21 days in two 40-bird groups caged in separate places with similar conditions. They were housed up to 41-days, until the end of the experiment.

Experimental design

A total of eighty 29-days old chickens were divided in eight groups including 10 chickens in each group. Four groups were Mg⁺ and four other groups were Mg⁻ including two 10-bird experimental groups, and two 10-bird control groups (Table 1). The housing conditions of the chickens were chosen similarly. Feed and water were provided as needed during the time of experiment. Blood samples were taken to determine H9N2 antibodies with hemagglutination inhibition (HI) test before inoculation. Two groups of chickens with Mg⁺ and Mg⁻ statues were inoculated intravenously (IV) through brachial vein, and the other two groups of chickens with Mg⁺ and Mg⁻ statues, were inoculated through both Intra Venous (IV) and Oculonasal (ON) routes with a volume of 0.2 ml of a 1:10 dilution of infectious AAF virus with the infectivity titer of 10^{7.5} ELD₅₀ (Embryo Lethal Dose 50. The four control groups were inoculated with sterile PBS. During 10 post inoculation days (PID), all groups were observed for clinical signs of disease and all

observations were recorded. During this period, necropsy was done on dead chickens, and all macroscopic lesions were recorded. At the end of experiment following 41 days, all survival birds were slaughtered for necropsy after blood sampling.

Intravenous Pathogenicity Index (IVPI) determination

According to the clinical signs and the number of dead birds during 10 post inoculation days, IVPI of the virus in different control and experimental groups were calculated using European standard method described for calculation of IVPI of Newcastle disease virus upon which the experimental design was modified by Alexander [3].

Antibody and virus detection

For virus isolation, tissue samples of trachea, kidney, lung thymus and bursa of fabricious collected from all dead and slaughtered birds were used. Standard procedures were used to reisolate the virus in embryonated chicken eggs and to confirm the H subtype of isolates according to the procedure described by Swayne *et al.*, [26]. Sera samples were obtained from all chickens at days 1, 7, 14 and 28 days post inoculation and from any surviving chickens in each group at day before slaughtering of the chickens. Blood samples were tested by the HI test using H9N2 subtype antigen as described by Swayne [26]. Rapid serum agglutination (RSA) test was done on all sera taken from Mg+ and Mg- groups on days 1 and 41 postinoculation to see if they are positive or negative [16].

Histopathologic examination

Tissue samples were collected from two dead birds in Mg+ experimental groups. The lung,, kidney, bursa of fabricious,, and thymus samples were fixed in 10% neutral buffered formalin, embedded in paraffin, sectioned in 5µm, deparaffinized and stained with Hematoxylin and Eosin (H&E) for histopathologic examinations.

Result

Clinical signs

No clinical signs were seen in the control groups. In the experimental groups, the clinical sings were observed at second, third or forth day post-inoculation (PID). The clinical signs generally were depression, crouching, huddling, ruffled

feathers, death and mild respiratory signs including coughing, sneezing and sometimes respiratory sounds especially in Mg+ groups. Two chickens died at 5th and 7th PID in Mg+ groups.

Gross pathology

Both of dead birds belonged to Mg+ chickens inoculated via both IV and ON routes or IV route alone. At the necropsy, the air sacs were cloudy and thickened. Numerous subepicardial petechial hemorrhages were present in heart. The kidneys were congested with foci of nephritis and urate deposition. The thymus was hyperemic with subcapsular petechial hemorrhages. Fibrinous cast in tracheal bifurcation and pulmonary hyperemia were observed, only in the chickens that died on 5th PID from IV and ON routs inoculated Mg+ group (Fig.1).



Figure 1 A 29-day old Mg+ chicken, was inoculated with a H9N2 subtype via IV & ON routes, and died 5th PID. Pulmonary hyperemia and fibrinous cast in tracheal bifurcation are present.



Figure 2 A 29-day old Mg+ chicken, was inoculated with a H9N2 subtype via IV route, died 7th PID. Severe nephritis and renal urate deposition are present.

Mild to severe nephrosis and urate deposition were seen in the kidney of two dead birds (Fig.2). The carcasses were congested and severe congestion was seen in the livers. Congestion and subcapsular petechial hemorrhages were seen in the spleen and bursa of fabricious.

Serologic detection of infection

Antibody against H9N2 subtype antigen was diagnosed in the sera samples of one-day old chickens in HI test; but the sera samples taken before inoculation on day 29, were all negative in HI test. All sera samples taken on 10 PID in experimental groups were positive against H9N2 in HI test with high antibody titers. All sera samples from control groups taken on 1st and 10th PID were negative in HI test (Fig.3). All sera taken on day 41 from Mg+ groups were positive and all sera taken from Mg- groups were negative in RSA test.

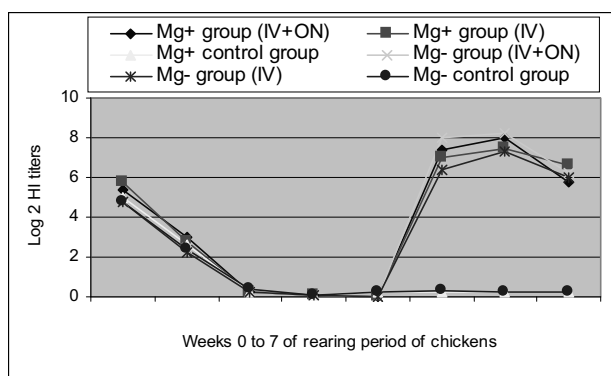


Figure 3 This figure shows the mean of H9N2 log 2 hemagglutination inhibition (HI) titers of 6 groups of Mg + and - commercial chickens from weeks 0 to 6 of rearing period. Groups 1 and 2 are Mg + chickens, were challenged respectively by IV along with ON and IV routs. Groups 3 and 4 are Mg - chickens, were challenged respectively by IV along with ON and IV routs. Groups 5 and 6 are control Mg + and Mg - chickens, were inoculated with sterile PBS as inocula.

Detection of viral infection

Following inoculation of the tissue suspension including kidney, bursa of fabricious, thymus, trachea, and lung obtained from slaughtered birds on the 10th PID, into allantoic cavity of embryonated chicken eggs, all embryos survived during 7 days post inoculation, and the collected AAF samples, were negative in HA test. Experimental groups: Following inoculation of birds, tissue suspension including kidney, bursa of fabricious, thymus, trachea and lung obtained from dead birds on 5th PID and 7th PID as well as slaughtered birds on 10th PID, some losses in embryos, were seen on 2 or 3 days after inoculation. The collected AAF of these eggs was positive in HA test and specific antiserum of H9N2 inhibited the hemagglutination activity of the allantoic fluids in HI test.

Histopathologic findings

Histopathologic examination revealed pulmonary congestion with mild infiltration of inflammatory mononuclear cells in lamina propria of secondary bronchi. Congestion, nonsuppurative focal interstitial nephritis, foci of hemorrhages, lytic necrosis, and hypercellularity of glomeruli were present (Fig.4-A, B & C). Mild to moderate generalized lymphocyte depletion, atrophy of lymphoid follicles, corrugation of epithelium and severe interfollicular edema were observed in the bursa of fabricious (Fig. 4-D). The reticular epithelium between the cortex and medulla were prominent (Fig. 4-E).

Table1 Intravenous pathogenicity index (IVPI) of amino allantoic fluid (AAF) of A/Chicken/Tehran/ZMT-173/99 (H9N2) strain via intravenous (IV) along with ocularnasal (ON) routes or IV rout alone in 29- day- old Mg positive and Mg negative chickens groups. Control groups were inoculated with sterile PBS as inocula.

Treatment groups	Inocula & inoculation		
	Inocula	IV & ON	IV
Mg positive group	AAF	0.3	0.2
Mg positive group (control)	PBS	0.00	0.00
Mg negative group	AAF	0.21	0.16
Mg negative group (control)	PBS	0.00	0.00

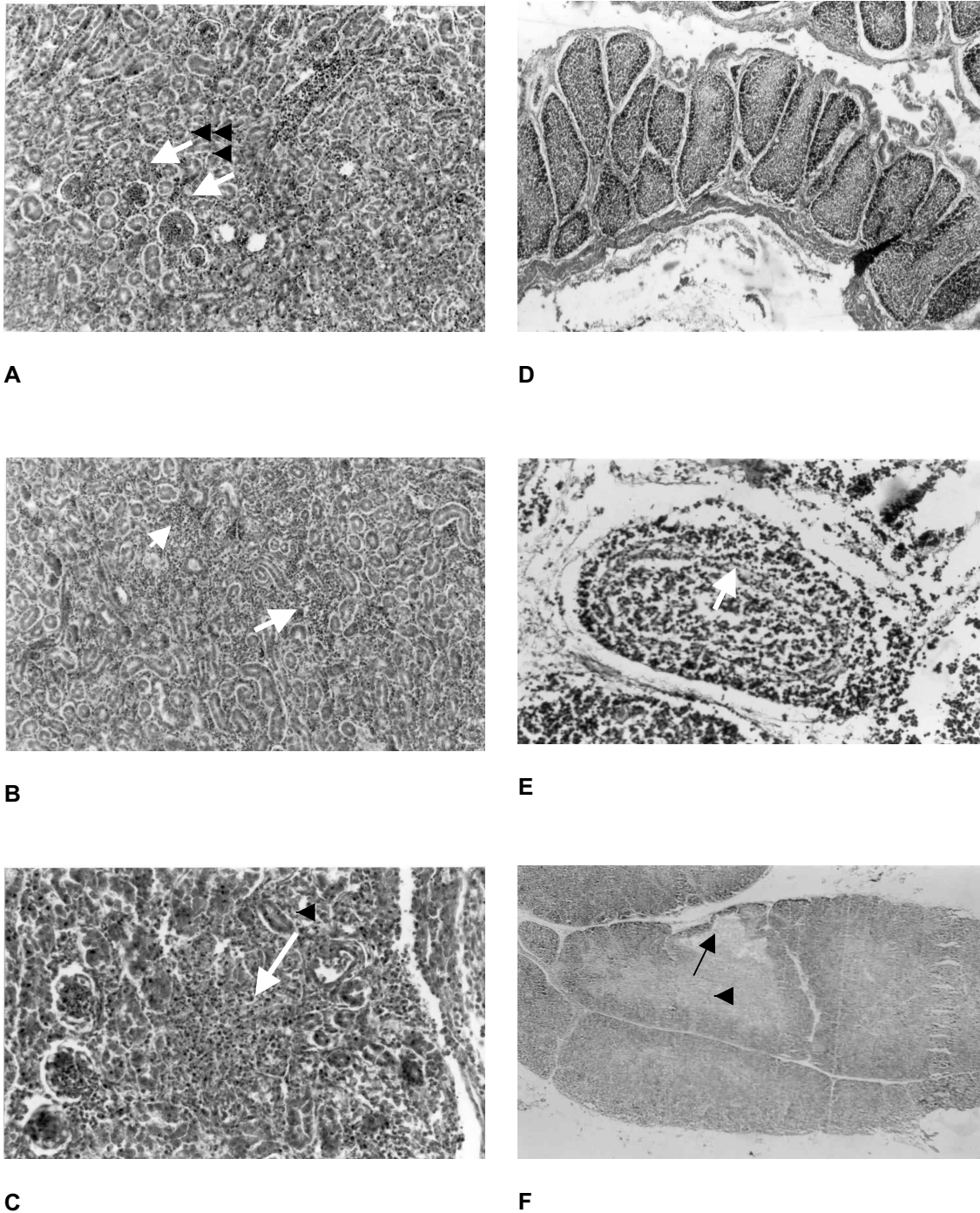


Figure 4 Histopathologic examinations of kidney from a 36-day old Mg + chicken, died 5th PID following inoculation via IV&ON routs (**Fig 4-A,B,C**), and bursa of fabricius and thymus from a 34-day old Mg + chicken died 7th PID following inoculation via IV rout (**Fig 4-D,E,F**). **Fig 4-A**) Congestion and hypercellularity of glomeruli and nonsuppurative focal interstitial nephritis (H&E, ×100); **Fig. 4-B**) Nonsuppurative tubulointerstitial nephritis (H&E, ×100); **Fig. 4-C**) Focal necrosis with granulocytic infiltration and necrotic debris (H&E, ×200); **Fig. 4-D**) Mild to moderate lymphoid depletion, atrophy of lymphoid follicles, and corrugation of epithelium of bursa of fabricius (H&E, ×40); **Fig. 4-E**) Moderate lymphoid depletion with prominence of reticular epithelium between cortex and medulla in a lymphoid follicle and severe interfollicular edema of bursa of fabricius (H&E, ×200) and **Fig. 4-F**) Sever hyperemia and focal depletion of lymphocyte population in the cortex of thymus (H&E, ×50).

Severe hyperemia, depletion of lymphocyte population in cortex and prominent reticuloepithelial cells and myocytes in medulla were seen in thymic lobules (Fig 4-F). The spleen was congested with mild lymphoid hyperplasia. Lymphoid tissues including thymus and bursa of fabricius were more severely affected in the chicken that died at 7 PID in Mg⁺ group inoculated via IV route alone. The liver sinusoids were congested and hepatocytes granular degeneration was present.

Discussion

During 1990-2007, outbreaks of MPAI caused by H9N2 subtype have been reported from Germany, Italy, Ireland, South Africa, Bulgaria, Korea, China, Hong Kong, Iran, Pakistan and other Middle Eastern countries [1,6,7,12,15,17,19]. In Iran, Vasfi Marandi and Bozorgmehri-Fard in 1998 isolated H9N2 subtype from the chicken flocks of Tehran province. This isolate didn't cause any losses in 29-days old inoculated chickens during experimental trials. Therefore, this virus has been defined as non pathogenic (NPAI) or non-Highly Pathogenic Avian Influenza (nHPAI) [28]. Besides, Similar results were obtained by Toroghi and Momayez in 2006 [27] and Pourbakhsh *et al.*, in 2000 [20]. Subsequent serological and virological studies showed that H9N2 isolates to be prevalent in the poultry farms, almost in all provinces of Iran [29]. These outbreaks caused great economic losses in poultry industry due to increased mortality and decreased egg production [31]. Asphyxiation of chickens resulting from bronchial casts has not been reported in experimental infection both in SPF and commercial chickens. This study was designed to investigate the pathogenic potential of A/Chicken/Tehran/ZMT-173/99(H9N2) strain in commercial chickens with Mg⁺ and Mg⁻ status.

As the results of this investigation shows, pathogenicity index of the virus was below 1. Despite of the 10 percent mortality in Mg⁺ groups, no great differences were seen between pathogenicity of H9N2 and its pathogenicity index obtained in this study in Mg⁺ and Mg⁻ chickens groups, (Table 1). Slemons *et al.*, (1991) characterized pathogenicity indices from 1.24 to 3 as HPAI viruses, according to the results of IVPI of 29 different strains isolated from waterfowls and other domestic and wild birds [24]. However; lack of correspondence between pathogenicity of H9N2 in experimental and field conditions has been

investigated by many researchers. It has been declared that the factors such as management, concurrent bacterial or viral diseases, immunosuppressive agents, age and strain of chicken, are the main reasons of the pathogenicity variation of LPAI isolates [1,5,7,12,15,17,27]. During the influenza outbreak of Italy in 1999-2000, there was reported variable mortality rate from 5% to 90%, depending on the age of the affected birds and the presence of secondary infections such as *P. multocida*, *O. rhinotracheale* and *M. galisepticum* [10]. Bano *et al.*, (2003) indicated that H9N2 subtype as a nonpathogenic virus can cause a severe infection in field condition in presence of opportunist secondary pathogens. They also showed that in chemically bursectomised chickens, H9N2 subtype can cause high mortality [7]. Kim *et al.*, (2006) showed that a Korean avian H9N2 influenza virus was able to cause 30% mortality and the reduction of egg production [15]. Guo *et al.*, (2000) reported that a Chinese H9N2 virus strain caused 80% mortality rates in 12-week old layer chickens, despite its failure to meet the criteria for HPAI viruses [12]. Banani *et al.*, (2002) and Nili and Assasi (2003) proposed that secondary bacterial infections such as *O. rhinotracheal*, *E. coli* and *M. galisepticum* may be more important enhancers of the clinical signs than the other factors in H9N2 infection in chickens [5,18] by producing a bacterial protease which helps to cleave, the cleavage site of HA proteins [8,21]. The results of this study showed that the 10 percent mortality occurred in experimental infection with A/Chicken/Tehran/ZMT-173/99 strain were due to the formation of casts in tracheal bifurcation and urate deposition (Fig 1 and 2). Although nephrosis and urate deposition in the kidney has been reported in recent years [13, 14], but bronchial cast in H9N2 infection has not been previously reported.

Mild respiratory changes observed in IV, IT (intra tracheal) and ON inoculated SPF chickens with a H9N2 subtype strain, indicated the effect of route of inoculation on induced disease [13,14]. In order to study the pathogenicity of A/Chicken/Tehran/ZMT-173/99 (H9N2) strain, we firstly inoculated Mg⁺ chickens by IV route alone, but formation of cast in tracheal bifurcation was not observed. Therefore, a novel experimental model including IVPI evaluation by using Mg⁺ chicken by IV along with ON routes concluding to bronchial cast formation was adopted in this study. This might explain why other researchers were not able to produce casts in

tracheal bifurcation in SPF or Mg- commercial broiler chickens in experimental infection by IT or IV or ON routes alone [13,14,20, 28].

In the two chickens that died in this experiment, kidney lesions were apparent in macroscopic and microscopic examinations, and this was predictable because of IV inoculation and real viremia. Vasfi Marandi and Bozorgmehri-Fard [29] indicated that congestion of kidney and urate deposits are observable signs which were seen in this study, too. The renal lesions which are mainly interstitial nephritis or tubulointerstitial nephritis were frequently reported in outbreaks of HPAI and nHPAI [9,11,14,23]. According to the renal lesions such as tubular necrosis and nephritis reported by Swayne *et al.*, [25] and detection of the virus from these sites, it can be suggested that kidneys are a suitable place for replication of AIV. However, since 1969, Slemons *et al.*, [24] and many other researchers [4,13,23] have indicated the nephrotropism nature and nephropathogenicity of AIV. Regarding the lesions observed in the kidney in necropsy and histopathologic examinations in the present study, it is suggested that early death caused by internal imbalance due to renal failure, may be the main reason of absence of respiratory signs such as pneumonia and fibrinous casts in tracheal bifurcation.

Necrotic depletion of lymphoid centers in infected turkeys has been described with Turkey/Ont/7732/66 strain. This strain also produced severe lymphoid necrosis in experimentally inoculated chickens; the necrosis was evident in lymphoid cells present in spleen, thymus, bursa, intestinal tract and lung [9]. In the present study, in chickens inoculated IV or IV along with ON rout, presence of hyperemia and apparent hemorrhages and lymphocytic cellular depletion in thymus seemingly indicates it's involvement during influenza disease. Presence of the same signs in bursa of fabricious along with the lesions in thymus can indicate the involvement of immune system and immunosuppression caused following H9N2 infection; but of course, further studies are needed to show such effect of H9N2 subtype on immune system.

Based on the results obtained, it is suggested that bronchial casts and sever nephritis with urate deposition are the principal cause of mortality in commercial Mg⁺ chickens inoculated IV along with ON routes. Eventual immunosupresion as well as bacterial co-infection such as *M. gallisepticum* and *E. coli* might increase the

pathogenicity of H9N2 infection. The discrepancies observed in the pathogenicity of H9N2 strain between this experimental infection and those reported by Toroghi and momayez in 2006 [27], Vasfi Marandi and Bozorgmehri-Fard in 2002 [28] and Pourbacksh *et al.*, in 2000 [20] may be due to strain of chickens used in the study, health status of commercial chickens, the routs of virus inoculation as well as strain of H9N2 viruses. Proteolytic cleavage of the influenza virus HA glycoprotein by cellular proteases is a prerequisite for virus infectivity, spread of the virus, tissue tropism, and viral pathogenicity. Some bacterial enzymes recognize a monobasic cleavage signal at HA of the mammalian and the nHPAI viruses [21]. Amino acid sequence analysis of HA gene cleavage site of A/Chicken/Tehran/ZMT-173/99 strain is crucial to demonstrate any probable change in the pathotype of virus.

ACKNOWLEDGEMENTS

This research was supported by a grant from the Research deputy of Faculty of Veterinary Medicine, University of Tehran. Also, the authors are grateful to Department of Clinical Science; Poultry Diseases Section (Tehran- Iran).

REFERENCES

- 1 Aamir, U.B., U. Wernery, N. Ilyushina, and R.G. Webster; 2007; Characterization of avian H9N2 influenza viruses from United Arab Emirates 2000 to 2003. *Virology* 361:45-55
- 2 Alexander, D.J; 2007; An overview of the epidemiology of avian influenza. *Vac* 30: 5637-5644.
- 3 Alexander, D.J; 1998; Newcastle disease virus and other avian paramyxoviruses. *A laboratory manual for the isolation and identification of avian pathogens*; 4th edition. Edited by Swayne, D.E., J.R. Glisson, M.W. Jackwood, J.E. Pearson, and W.M. Reed, *Am. Assoc. Avian Pathol* 156-163.
- 4 Alexander, D.J., S.A. Lister, M.J. Johnson, C.J. Randell, and P.J. Thomas; 1993; An outbreak of highly pathogenic avian influenza in turkeys in Great British in 1991. *Vet Rec* 132:535-536.
- 5 Banani, M., R. Momayez, S.A. Pourbakhsh, H. Goodarzi, and M.A. Bahmani-Nejad; 2002; Simultaneous isolation of Ornithobacterium rhinotracheal and avian influenza virus subtype H9N2 from commercial poultry. *Iranian J Vet Res* 3:190-195.
- 6 Banks, J., E.C. Specidel, P.A. Harris, and D.J. Alexander; 2000; Phylogenetic analysis of influenza A viruses of H9 haemagglutinin subtype. *Avian Pathol.*, 29:353-360.
- 7 Bano, S., K. Naeem, and S.A. Malik; 2003; Evaluation of pathogenic potential of avian influenza virus serotype H9N2 in chickens. *Avian Dis* 47:817-822.

- 8 Callan, R.J., F.A. Hartmann, S.E. West, and V.S. Hinshaw; 1997; Cleavage of influenza A virus H1 hemagglutinin by swine respiratory bacterial proteases. *J Virol* 71: 7579-7585.
- 9 Calnek, B.M., H.J. Barnes, C.H. Beard, L.R. McDougald, and M. Saif (eds); 1997; *Diseases of poultry, 10th ed.* Iowa state university press, Ames, Iowa, USA, 586-605.
- 10 Capua, I., and D.J. Alexander; 2004; Avian influenza: recent developments. *Avian Pathol* 33: 393-404.
- 11 Daryl, C.J. and B.G. Maxfield; 1976; An occurrence of avian influenza virus infection in laying chicken. *Avian Dis* 20:422-423.
- 12 Guo, Y.J., S. Krauss, D.A. Senne, I.P. Mo, K.S. LO, X.P. Xinog, M. Norwood, K.F. Shortridge, R.G. Webster, and Y. Guant; 2000; Characterization of the pathogenicity of members of the newly established H9N2 influenza virus lineages in Asia. *Virol* 267:279-288.
- 13 Hablolvarid, M.H., I. Sohraby Haghdoost, S.A. Pourbakhsh, and M.R. Gholami; 2004; Histopathological study of intratracheally inoculated A/Chicken/Iran/259/1998(H9N2) influenza virus in chicken *Arch Razi Inst* 58:51-62.
- 14 Hablolvarid, M.H., I. Sohraby Haghdoost, S.A. Pourbakhsh, and M.R. Gholami; 2003; A study on histopathologic changes in chicken following intravenous inoculation with avian influenza virus A/Chicken/Iran/259/1998(H9N2) influenza virus in chicken *Arch Razi Inst* 55:41-54
- 15 Kim, J.A., S.H. Cho, H.S. Kim, and S.H. Seo; 2006; H9N2 influenza viruses isolated from poultry in Korean live bird markets continuously evolve and cause the sever clinical signs in layers. *Vet Microbial* 118:169-176.
- 16 Kleven, S.H; 1998; Mycoplasmosis; *A laboratory manual for the isolation and identification of avian pathogens; 4th edition.* Edited by Swayne, D.E., J.R. Glisson, M.W. Jackwood, E. Pearson, and W.M. Reed, *Am Assoc Avian Pathol* 74-80.
- 17 Naeem, K., A. Ullah, R.J. Manvell, and D.J. Alexander; 1999; Avian influenza A subtype H9N2 in poultry in Pakistan. *Vet Rec* 145:560.
- 18 Nili, H. and K. Asasi; 2003; Avian influenza (H9N2) outbreak in Iran. *Avian Dis* 47:828-831.
- 19 Perk S., C. Banet-Noach, E. Shihmanter, S. Pokamunski, M. Pirak, M. Lipkind, and A. Panshin; 2006; Genetic characterization of the H9N2 influenza viruses circulated in the poultry population in Israel. *Comp Immunol Microbiol Infect Dis* 29:207-223.
- 20 Pourbakhsh, S.A., M. Khodashenas, M. Kianizadeh, and H. Goodarzi; 2000; Isolation and identification of avian influenza virus H9N2 subtype. *Arch Raz Inst* 51:27-38.
- 21 Rott R., H.D. Klenk, Y. Nagai, and M. Tashiro; 1995; Influenza viruses, cell enzymes, and pathogenicity *Am J Respir Crit Care Med* 152: S16-9
- 22 Senne, D.A; 1998; Virus propagation in embryonating eggs; *A laboratory manual for the isolation and identification of avian pathogens; 4th edition.* Edited by Swayne, D.E., J.R. Glisson, M.W. Jackwood, J.E. Pearson, and W.M. Reed, *Am Assoc Avian Pathol* 235-240.
- 23 Shalaby, A.A., D. Richard, D. Slemons, and E. Swayne; 1994; Pathological studies of A/Chicken/Alabama/7395/75 (H4N8) influenza virus in specific-pathogen-free laying hens. *Avian Dis* 38:22-32.
- 24 Slemons, R.D., P.K. Condober, and D.E. Swayne; 1991; Assessing pathogenicity potential of water fowl origin type A influenza viruses in chicken. *Avian Dis* 35:210-5.
- 25 Swayne, D.E., M.L. Perdus, M., Garcia, R. Rivera-Cruz, and M. Brugh; 1997; Pathogenicity and diagnosis of H5N2 Mexican avian influenza viruses in chickens *Avian Dis* 41:335-346.
- 26 Swayne, D.E., D.A. Senne, and C.W. Beard; 1998; Avian influenza; *A laboratory manual for the isolation and identification of avian pathogens; 4th edition.* Edited by Swayne, D.E., J.R. Glisson, M.W. Jackwood, J.E. Pearson, and W.M. Reed, *Am Assoc Avian Pathol* 150-155.
- 27 Toroghi, R., and R. Momayez; 2006; Biological and molecular characterization of avian influenza virus (H9N2) isolates from Iran. *Acta virol* 50:163- 168
- 28 Vasfi Marandi, M. and M.H. Bozorgmehri-Fard; 2002; Isolation of H9N2 subtype of avian influenza viruses during an outbreak in chickens in Iran. *Iranian Biomed J* 6:13-17.
- 29 Vasfi Marandi, M., M.H. Bozorgmehri-Fard, and S.M. Tabatabaie, S.M; 2003; A seroepidemiological study of avian influenza (H9N2) in Iran. *J Sch Vet Med; Shahid Chamran Univ* 8:23-34.
- 30 Vasfi Marandi, M., M.H. Bozorgmehri-Fard, and M. Hashemzadeh; 2002; Efficacy of inactivated H9N2 avian influenza vaccine against non-highly pathogenic A/Chicken/Iran/ZMT-173/1999 infection. *Arch Razi Inst* 53:23-32
- 31 Vasfi Marandi, M., M.H. Bozorgmehria-Fard, S.A. Hassani Tabatabaie, M. Kerdabadi, S. Charchkar, and M. Farahmandi; 2000; Serological monitoring of hemagglutination inhibition antibodies in a multi aged layer farm following avian influenza due to H9N2 subtype between 1998-1999 in Iran. *J Fac Vet Med Univ. Tehran, Iran.* 55:73-81
- 32 Webster, R.G., W.J. Bean, O.T. Gorman, T.M. Chambers, and Y. Kawaoka; 1992; Evolution and ecology of influenza A viruses. *Microbiol Rev* 56:152-179.