

Review Article

Impact of Viral Nervous Necrosis (VNN) Disease as a New Threat to Global Fisheries and Aquaculture Development- A Review

Zorriehzahra M¹, Hassantabar F², Ziarati M^{3*}, Yazdanpanah Goharrizi L⁴, Seidgar M⁵, Radkhah K⁶, Sheikh Asadi M⁴

1. Department of Scientific Information and Communication, Iranian Fisheries Science Research Institute (IFSRI), Agricultural Research Education and Extension Organization (AREEO), Tehran, Iran.
2. Department of Fisheries Science, Sari Agricultural Sciences and Natural Resources University, Sari, Mazandaran, Iran.
3. Department of Microbiology, Islamic Azad University, Jahrom Branch, Jahrom, Iran.
4. Animal Sciences Research Department, Kerman Agricultural Research and Education Center, Agricultural Research Education and Extension Organization (AREEO), Kerman, Iran.
5. National Artemia Research Center, Iranian Fisheries Science Research Institute, Agricultural Research, Education and Extension Organization, Urmia, Iran.
6. Department of Aquatic Animal health & Diseases, Iranian Fisheries Science Research Institute (IFSRI), Agricultural Research Education and Extension Organization (AREEO), Tehran, Iran.

Abstract

Viral Nervous Necrosis (VNN) also known as Viral Encephalopathy and Retinopathy (VER), is a hazardous and devastating disease of many species of cultured and marine fish worldwide. It is caused by Betanodaviruses, a serious concern especially in larvae and juvenile fish. This virus infects most of the cultured fish causing severe mortality. Our current review focuses chiefly on recent studies performed on VNN disease. Recent outbreaks have been reported in China, Indonesia, Singapore and India, affecting the mariculture and aquaculture industries. It has also led to the dramatical decline of mullet stocks in the Caspian Sea. The four main genotypes of Betanodaviruses were found in all continents except South America. The economic loss due to the virus is mainly due to mortality and spread of infection both vertically and horizontally. More research and epidemiological surveys should be conducted, especially in critical areas, where mariculture farms are planned to be established. Therefore, finding new rapid diagnostic tools, monitoring and surveillance programs, and effective vaccines, for the control, prevention and eradication of this disease should be considered globally.

Keywords: Viral Nervous Necrosis, Fish, Mariculture

Introduction

Viral Nervous Necrosis (VNN) is a potential viral disease affecting more than 120 invertebrate and fish species in the world (1) and has caused serious economic damage over the past few years (2).

It belongs to the genus Betanodavirus and consists of segmented RNA genome (3). VNN disease is considered as one of the most widespread and destructive viral infections of fish (4-5-6) and also has global distribution with a broad range of hosts. It can cause severe disease and great economic loss in marine and freshwater fish with no treatment or commercial vaccine available up to now (7-8). The Betanodavirus is a non-enveloped, icosahedral shaped member of the family of Nodaviridae. The diameter of the virion is 25-30 nm and contains two segments of single-stranded

* **Corresponding author:**

Mina Ziarati.

Email: mziarati2@ gmail.com.

RNA (9). The genera of this family are alphanodavirus that primarily infects insects, Betanodavirus which are [pathogens of fish and a third category which proposed to be named gammanodavirus that infects shrimp and prawns (10-11).

Outbreaks of Betano-davirus in fish populations are reported from salt and freshwater. Based on the coat protein gene sequence, Betanodaviruses have four main genotypes; Barfin Flounder NNV (BFNNV), Tiger Puffer NNV (TPNNV), Striped Jack NNV (SJNNV), and Red Spotted Grouper NNV (RGNNV) (12-13) and can infect wild and farmed fish between the temperature range of 16 to 30°C. VNN infection has been proved in more than 50 fish species (3).

The mortality rate due to VNN in the early larval and juvenile stages is remarkably more than in adult fish. VNN is reported to be responsible for the dramatical decrease of mullets stock in the Caspian Sea (14-15-16) causing disease outbreaks in hatchery-reared larvae and juveniles (7,17-18-19-20), fish mortality and economic loss in farm and cage reared fish (7,21-22-23).

Virus genome and morphology

Betanodaviruses are non-enveloped and spherical. The average diameter of the viral capsid is only 37 nm. Its RNA strand is split into two sections RNA1 and RNA2 that together account for 3.5 kbp (approx.) that encode 3 genes. Genomes are linear and segmented, bipartite, around 21.4kb in length (24).

The nonenveloped virion is about 30 nm in diameter with a T=3 icosahedral symmetry (180 protein subunits) (Fig. 1). The genome of betanodavirus is composed of RNA1=3.1 kb and RNA2=1.4 kb. Each genome segment 5' end is capped. The 3'end has no poly (A) tail.

The virion RNA is infectious and serves as both the genome and viral messenger RNA.

RNA1 encodes the RNA-dependent RNA polymerase (protein A) directly, and RNA2, the capsid protein.

A subgenomic RNA (sgRNA3), 3' co-linear to RNA1 is also produced and encodes proteins B1 and B2. Thus the RNA1 gene encodes the

viral replicase and the RNA2 segment encodes the structural capsid protein. A third gene called RNA3, which is included in the RNA1 segment, codifies non-structural proteins with antiapoptotic and RNAi-inhibiting activities that interfere with the cellular defense mechanism, thus favoring viral replication (25).

Replication/transcription events

Positive stranded RNA serves both as genomic and mRNA for these viruses. The 5' may be naked, capped or covalently linked to a VPG protein.

The 3' may be either naked or polyadenylated. Upon infection, the genomic/mRNA is translated, often into a polyprotein encoding for replication machinery. The replication occurs in membranous invaginations of the REG, possibly to avoid dsRNA intermediate detection.

Replication of the positive strand presumably leads to dsRNA formation, which in turn will be transcribed into positive single stranded genomic/mRNA. The neo-synthesized RNA may serve either for replication or translation.

1. Replication:

The path to the virus into the cytoplasm after localization and attaching: 1- Virus penetrates into the host cell. 2- Uncoating and release of the viral genomic RNA into the cytoplasm. 3- The viral RNA-1 is translated to produce the RdRp protein. 4- Replication takes place in cytoplasmic viral factories. A dsRNA genome is synthesized from the genomic ssRNA (+). 5- The dsRNA genome is transcribed /replicated thereby providing viral mRNAs/new ssRNA (+) genomes. 6- Expression of the subgenomic RNA-3. 7- Translation of RNA-2 encoding capsid protein alpha. 8- Virus assembly in the cytoplasm around genomic RNA1 and RNA2. 9- Assembled capsid protein alpha is cleaved into capsid protein beta and gamma. 10- Release of infectious particles (lysis) (27) (Fig. 2). The virus multiplies within the cytoplasm. Entry into the host cell is achieved by penetration into the host cell. Replication follows the positive stranded RNA virus, replication

model. Positive stranded RNA virus transcription, using the internal initiation model of sub-genomic RNA transcription is the method of transcription. Vertebrates and invertebrates

serve as the natural host. Transmission routes are contact and contamination (28).

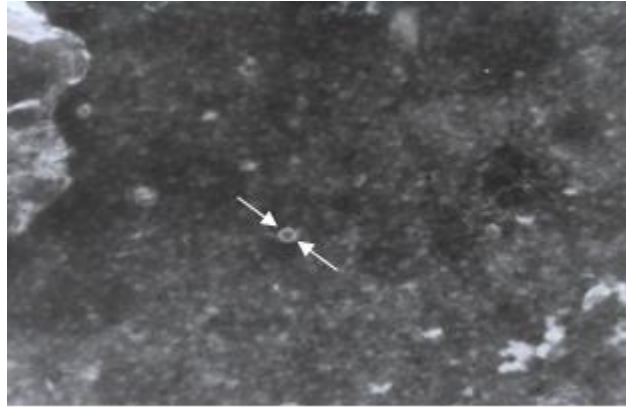


Fig 1. Icosahedra-shaped particle was similar to VNN in the specimen from Gilan. PTA staining. Mag. $\times 48000$ (26)

The widespread expansion and multiplicity of hosts

The Betanodavirus can escape the host defense system and replicate and transfer to other cells and also remain hidden in them, therefore the host keeps the infection (29), and transmits it horizontally and vertically (1) through a number of susceptible hosts and environment, the intensification of trade and cultivate the fish in virus-sensitive species (30).

Betano-davirus hosts have grown a lot since its first report so far (31) in wild and farmed fish and even freshwater fish (25), because of the increase in fish imports from different countries (32).

On the other hand, Betanodavirus has two strand RNA that can do virus reassortment. Evidence from research in 2017 suggests this genetic process. Sequence analysis revealed a certain genetic similarity between different species and identified human activities such as trade and transport of fish in the spread of disease (7). Viral reassortant is specific to the RNA genome, which accelerates the mechanism of evolution, infections of new hosts and inhibits host immune responses (1).

Marine fish are the most susceptible species and a few species are resistant because of lack of symptoms (31). Even before some fish such as Zebrafish and Goldfish were resistant (33),

but with the spread of disease in recent decades, they are susceptible (34).

The high homology of the sequence isolated from saltwater fish with the sequence from ornamental fish in freshwater has suggested the commercial exploitation of freshwater fish by sea fish (35).

In the mortality of fish, Vendriman *et al.* (36) revealed the close relationship between marine and farmed sequences, indicating the circulation of the virus between marine and wild fish (37). Figure 3 illustrates the spread of the virus around the world.

Viral infection in different fish through various conditions and factors

In Japan, in 1985, VNN was detected in parrotfish (*Oplegnathus fasciatus*) from clinical signs. After that in 1990, for the first time, Betanodavirus was reported as an agent of mortality in farmed fish (37) and the first report of piscine nodavirus was isolated from winter flounder in Atlantic Canada.

In Korea, in 1991, the first definition of the disease was reported in the farmed grouper although the viral agent was not identified (38). In the following years, various reports were provided in marine and farmed grouper in countries in Asia and the Mediterranean (23, 39-44).

Impact of Viral Nervous Necrosis (VNN) Disease as a New Threat to Global Fisheries and Aquaculture Development- A Review

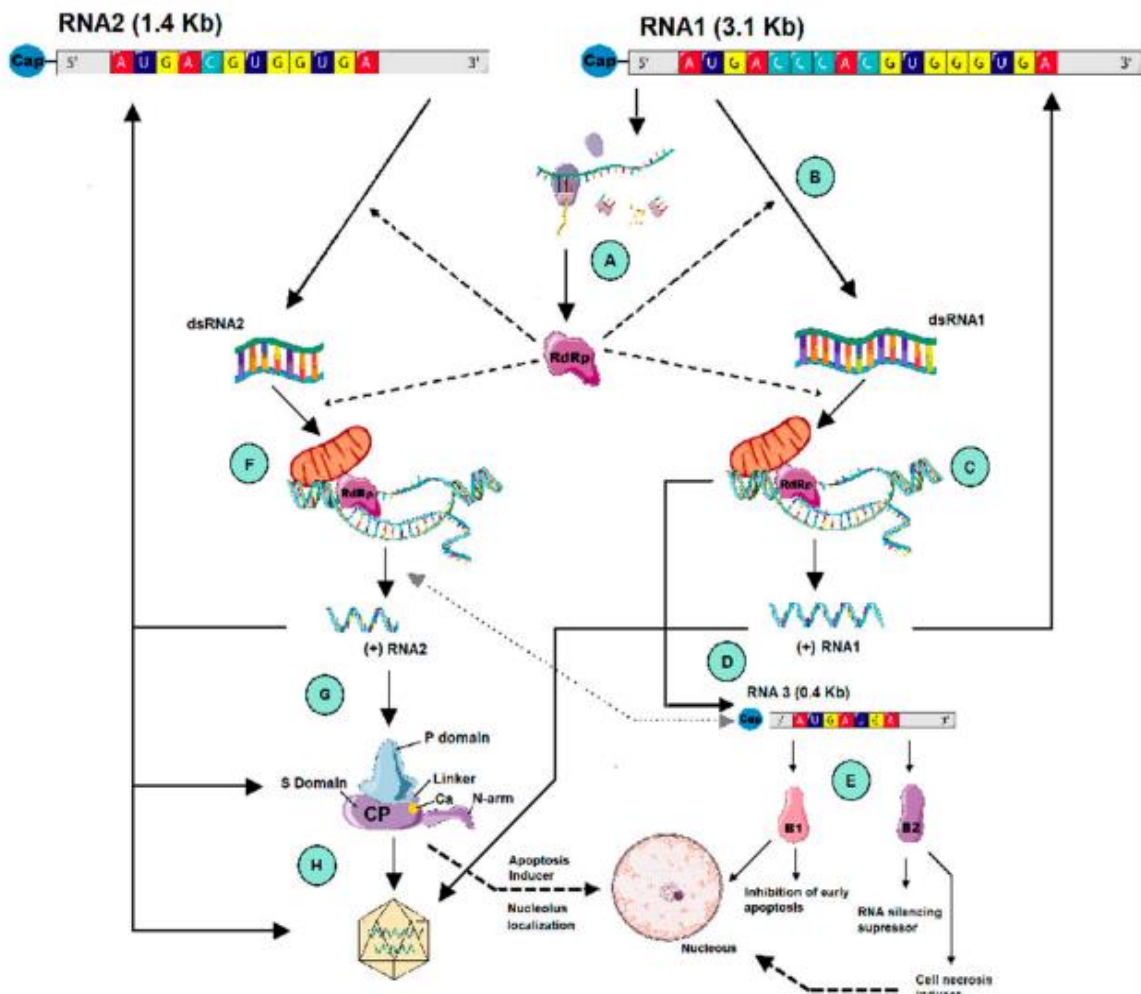


Fig 2. Schematic overview of the betanodavirus replication (<http://smart.servier.com/>)

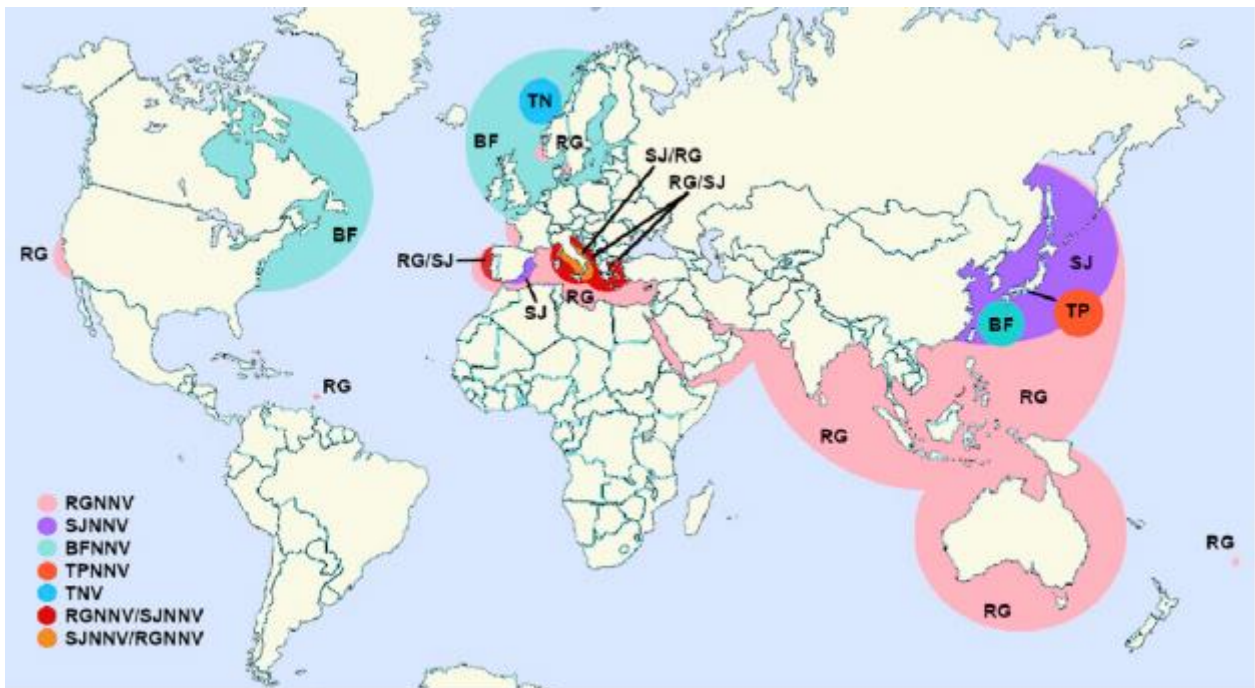


Fig 3. Distribution of Nervous necrosis virus (NNV) genotypes in the world (<http://smart.servier.com/>)

The virus genomic analysis suggests that a viral agent can be present in water and only infect susceptible fish (45). Water temperature, size and age of the host, and the dose of the virus can be considered important factors in the pathogenesis of betanodavirus (31).

In this way, smaller and younger fish are more sensitive (46), and the higher the temperature and the greater the dose, the greater the incidence of clinical symptoms (31).

Also, different studies showed the influence of temperature on Betanodavirus infection in various types of fish species (7-47).

Changing environmental conditions cause stress in fish which can play an important role in the growth and spread of the virus.

Relatively high water temperatures and low volatility contribute to the growth and replication of the virus and the transmission of the virus from one place to another due to water currents, migration of wild fish and fish cultivation facilities (48). The thermal dependence is mainly determined by RNA1 and the species' tropism is also determined by RNA2. Due to the segmented nature of their genome, VNN can generate reassortant viruses and create new hosts (7).

In addition, the effect of climate change on VNN infection has been reported in Indonesia on grouper fish (48). So, VNN can be pathogenic in different weather conditions.

For example, genotype RGNNV is most abundant in warm water with an optimum temperature of 25 to 30 °C and in fish such as Asian sea bass, European sea bass and grouper. BFNNV infects coldwater marine fish like flounder at an optimum temperature of 15 to 20 °C. SJNNV is typical at 20-25 °C in different fish and TP is specific at 20 °C in Tiger Puffer (49). It has been made clear that the temperature of the water is effective in determining the appearance and severity of VNN disease (50).

It is assumed that fish trade around the world contributes to the adaptation of the virus to different environmental conditions and the creation of a new host. In the future, water will be significant in the compromise and mole-

cular evolution of the virus species in geographic areas with different temperatures (35).

Table 1. Some listed marine or farmed species susceptible to VNN

Fish species	Common name	Key ref
Marine species Or Farmed specie	Sea bass	11,51-52-53-54-55
	Rock fish	52
	Sea bream	7,56-57
	Parrotfish	12,37
	Tuna fish	58
	Cobia	59
	Pompano	22,59
	Striped Jack	12,60
	Grouper	9,12,40,61-62-63-64-65-66
	Tiger puffer	12,66
	Senegalese sole	11
	Flounder	67
	Atlantic halibut	68
	Turbot	69
	Cod	55,70
Haddock	71	
Shrimp	72	

Table 2. Some listed Ornamental species susceptible to VNN

Fish species	Common name	Key ref
Ornamental fish species	Guppy	23
	Zebrafish	73
	Goldfish	34
	Blenny	74
	Medaka	75

Table 3. listed wild species susceptible to VNN

Fish species	Common name	Key ref
wild species	Cardinal fish, Grenadier, Eel, Slimehead	76
	Rockfish	52
	Bogue, Black goby, Horse mackerel, Garpike, Whiting, Hake, Pilchard, Gurnard	77
	Flounder	71
	Mullet	14,77
	Scad	52
	Scraper	78
	Filefish	52
	Grouper	36
	Shellfish, Crab, Shrimp, Mussel	78

Table 4. Some listed freshwater species susceptible to VNN

Fish species	Common name	Key ref
Freshwater species	Cod	13
	Black bass, Pick-perch	21
	Tilapia	79
	Sturgeon	80
	Eel	59
	Catfish	13,59
	Giant prawn	81

Impact of Viral Nervous Necrosis (VNN) Disease as a New Threat to Global Fisheries and Aquaculture Development- A Review

Fig 4. Exophthalmia (large arrow) observed in naturally VNN infected Grey mullet. B: brain. SC: spinal cord (26)




Fig 5. VNN-associated vacuolation in the eye (left) and in the brain (right) (109)

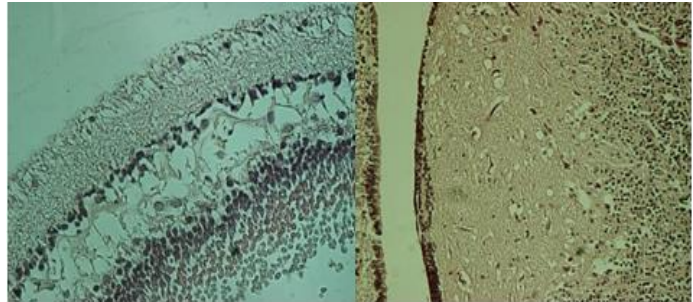
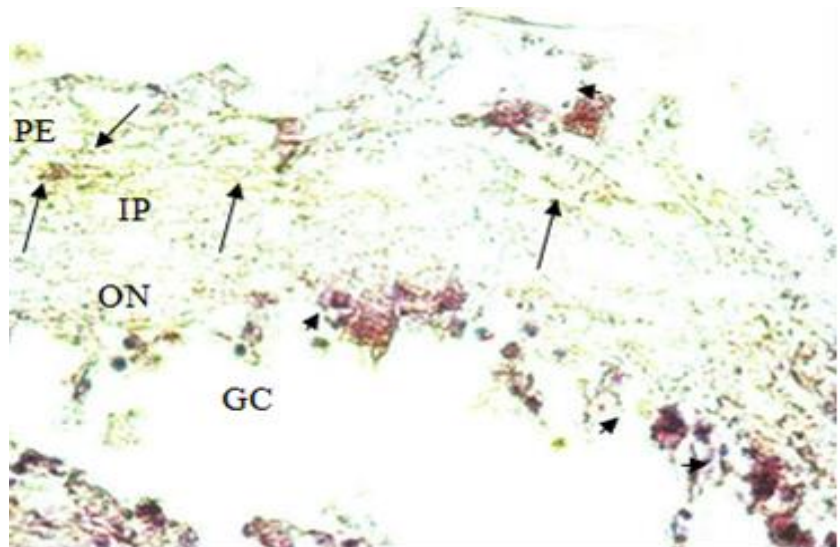


Fig 6. Hyperinflation of the swim bladder (left) and abdominal extension (right) in VNN infected *Liza aurata* in the Caspian Sea (14)



Fig 7. Positive reactions in IHC against VNN in retina of infected Grey mullet. Immunolabeling (large arrows) in the PE: pigment epithelium, ON: outer nuclear layer, IN: inner nuclear layer, IP: inner plexiform layer, GC: ganglion cell layer. Basophilic cells (small arrows), $\times 100$ (26)



Target organs and pathogenesis

VNN can enter the body through several tissues, such as the nasal cavity, the intestinal epithelium and intact skin. These routes were reported in infected sevenband groupers (*Epinephelus septemfasciatus*), spotted coral groupers (*Plectropomus maculatus*), and European sea bass larvae.

Some studies indicate that pathological changes first developed in the olfactory lobes and then spread to the abnormal brain tissue, medulla oblongata, spinal cord and finally to the retina (82-83-84-85).

Direct entry of VNN into the nerve cell through axonal transport to the brain stem via cranial nerves is another hypothesis (84-86).

The central nervous system (CNS) including the brain, spinal cord, and retina are the main target organs in which the virus actively replicates (16, 26, 69) (Fig. 4). Nguyen *et al.* (87) indicated that in striped jack, nerve cells in the spinal cord, particularly the area just above the swim bladder, were initially affected and then spread to the brain and finally to the retina. Although the virus is neurotropic, it is possible to detect the viral particles in non-nervous tissues, including liver, kidney, digestive tract, heart, spleen, anterior and posterior intestine, gonadal fluid, fins and gills using IHC/ISH or molecular techniques (68, 82, 88, 89, 90, 91, 92, 93). These authors suggest that the viral antigens first appear in the nervous tissues, where the virus has the highest persistence and the other organs are not generally believed to play an important role in the disease pathogenesis (92).

Although the swim bladder hyperinflation has been described in most of the infected fish with clinical signs of VNN, this is not considered to be a target organ for betanodavirus because no marked histopathological changes have been observed (85). In addition, the distribution of VNN in other tissues varies with fish species and age. Nodavirus disease causes highly consistent histopathological lesions, including severe widespread necrosis and vacuolation throughout the central nervous system (CNS) and all retinal layers of the affected fish (66).

The intra- or extracellular vacuoles or vacuolating encephalopathy can be seen in the grey matter of the olfactory bulb, telencephalon, diencephalon, mesencephalon, cerebellum, medulla oblongata, and in the dendritic cell of the spinal cord, particularly in the cranial part (35, 66, 68, 82, 92, and 94). Gliosis may also be found in the CNS.

The emersion of vacuolization is generally associated with the appearance of the neurological signs of the disease (95).

In the retina, massive necrosis of small round cells and spongiotic vacuolization are mainly present in the bipolar and ganglionic nuclear layer (92). Other histological lesions in the nervous tissues of infected fish include karyorrhexis, shrinkage, basophilia, the granularity of the neuropil, inflammatory infiltration, neuronal degeneration, pyknosis and cell lysis (1, 37, and 66).

Histopathological findings

The most common histopathological findings are vacuoles in the nervous system including the olfactory bulb, retina, optical nerve, spinal cord and different parts of the brain (35, and 96). The virus is detectable in other organs such as gonad, stomach, intestine, kidney and liver and body fluids. The VNN can infect wild fish as well as farmed fish (88). Distinct histopathological findings in different species are forming of vacuoles and necrosis in the nervous tissue. Lesions are observed in some parts of the brain including the forebrain, midbrain, hindbrain, medulla oblongata, spinal cord and granular layer of the retina (97-98-99).

Zorriehzahra *et al.* (96) detected VNN in the brain, optical nerve and retina of wild golden grey mullet (*Liza auratus*) and leaping mullet (*Liza saliens*). Also, swim bladder distention in mature captured *Liza auratus* was reported in the Caspian Sea (100). Following lesions appearing in the central nervous system (CNS) and retina fish which are affected show abnormal swimming, looping swimming and belly up rest, circular swimming, erratic swimming, spiral swimming (101), and deformity of the vertebral column (17).

Impact of Viral Nervous Necrosis (VNN) Disease as a New Threat to Global Fisheries and Aquaculture Development- A Review

The histological lesions of VNN include severe degeneration, pyknosis, shrinkage and basophilic cells in affected areas and vacuolation throughout the central nervous system of the fish and all retinal layers. The main target tissues are the nerve tissues especially the central nervous system (CNS) and the eye (retina) (8).

The distinctive histopathological signs of naturally betanodavirus-infected fish are necrosis with vacuolization of the nerve cells in the central nervous system and the retina (84).

The brain and eye were found to have the highest VNN titer and copy number. The gill, spleen and kidney also showed higher VNN titers than the other non-nervous tissues, suggesting that these tissues can be used for VNN diagnostics although they do not seem to represent the infective tissues (84). Affected fish displayed specific immunolabelling in the epidermal cells or the intestinal epithelial cells, concurrently with the nerve cells of the CNS in the early stages of betanodavirus infection, suggesting that the epithelium was a possible portal of entry for the virus (84). The spinal cord and brain of the affected fish showed vacuolation and pyknosis coinciding with marked shrinkage and basophilia of affected cells (102).

Besides, enzyme-linked immunosorbent assays (ELISA) and RT-PCR have been developed as detection tools and conventionally, the virus can be observed via transmission electron microscopy (TEM) (3).

Damage may occur in different parts of the brain, and the spinal cord and the granular (nuclear) retina of the cone and cylindrical cells and the coverage tissue around the germline layer (94).

The histopathologic lesions associated with the infection with betanodavirus clearly indicate that the virus has a high initial tendency to neural tissue (neurotropism) and has a high reproductive site in the CNS and the retina (8). One of the earliest positions of the virus replication in the *Pseudocaranx dentex* is the spinal cord, and then the virus can migrate from this site to the brain and ultimately migrate through the optic nerve to the retina (87).

In the brain and retina, infected larvae of fish can be seen to have large vacuoles, together with severe congestion of the blood vessels.

Larger fish also showed vacuoles and congestion in nervous tissue. Vacuolated cells and vacuoles are mainly present in the bipolar and ganglionic nuclear layer of the retina in the eyes (68,103-104-105). A common finding in the CNS is gliosis (1, and 13). In the telencephalon, diencephalon and the cerebellum vacuolated cells and larger vacuoles were mainly apparent (8, 65, and 104).

In the nerve cells, small vacuoles and strong basophilic inclusions are seen. The most prominent vacuolation is usually found in the grey matter of the optic tectum and cerebellum and there is often involvement of Purkinje cells (13,106).

Vacuolated cells and vacuoles are mainly present in the bipolar and ganglionic nuclear layer of the retina in the eyes (8, 68, and 103-104-105).

A common finding in the CNS is gliosis (1, and 13). Vacuolation can also be seen in the white matter; adjacent to the ventricles. These vacuoles appear to be intracytoplasmic, but their exact position cannot always be determined (107-108).

Studies have shown the location of immunopositive cells. This demonstrated that the virus enters the CNS along the nerves and blood vessels during the viremic stage of infection (8, 13, 69, and 104). Severe vacuolation in the outer nuclear layer, inner nuclear layer and ganglion cell layer of the retina and brain were observed in fish (109) (Fig. 5). Virus lesions in organs evaluated via histopathology can show viral tissue tropism. Histopathological signs may be different based on age and species. The virus proliferates in nerve cells.

Nguyen et al. (87) believed that nervous necrosis virus proliferation at early stages of *Pseudocaranx dentex* occurs in the neural cord. The virus then migrates to the brain, optical nerves and eventually to the retina.

In another study, histological findings showed extensive vacuolation and neuronal necrosis of the olfactory bulb and the optic lobe of the forebrain and the inner and outer nuclear layer of the retina (101).

Virus antigen was detected in the olfactory bulb so virus migration through the nasal cavity is proposed (82, and 88).

The virus was detected in viscera of fish including bile ducts in the liver, the mucosal epithelium of intestine and stomach, as well as tubular epithelial cells of the kidney. It supports the hypothesis of viral contamination by body fluid and feces. Water and food could be the easiest pathway. Hyperinflation of swim bladder has been reported from different fishes such as Asian sea bass (*Lates calcarifer*), European sea bass (*Dicentrarchus labrax*), and white trevally (*Pseudocaranx dentex*) (14, 54, 63, and 66) (Fig. 6).

Also, Nopadon *et al.* (101) described cystitis in swim bladder which correlated with abdominal distention in sea cage reared spotted coral groupers (*Plectropomus maculatus*).

Darkening of skin and trauma and lesions around the jaws and redness around the head probably due to vision problems in fish leading to the collision was observed (17,104,110).

The number and extent of lesions and their effects mostly depend on species and age of fish. Lesion effects on larvae and juvenile are more harmful than in other life stages. Besides the presence of vacuoles in nervous system pyknosis, karyorrhexis and karyolysis of neural cells were observed (17, 37, and 98).

Basophilic intracytoplasmic inclusion bodies in Japanese parrotfish and brown spotted grouper have been reported.

Diagnostic tests

Various methods could be employed such as histopathology followed by immunostaining, cell isolation and culture followed by immunostaining or PCR, transmission electron microscopy (TEM), immunohistochemistry test (IH-CT) (Fig. 7), indirect immunofluorescent antibody test (IFAT), reverse-transcription polymerase chain reaction (RT-PCR), RT-PCR followed by sequencing and Real-time PCR (3).

In our recent investigation on the rapid diagnosis of VNN in golden grey mullet (*Liza auratus*) in the Caspian Sea, Nested RT-PCR was also approved to be a suitable method for

rapid detection of the low level of infection that can detect low viral particles in asymptomatic carrier fish (111).

Potential risk to mariculture and its spread in freshwater aquaculture

Marine or brackish water fish culture on coastal areas and the development of sea cage culture has led to an increase in fish production (112). Recently, habitat loss and overfishing, and the spread of pathogens have led to the current decrease of fish stocks that indicates the necessity of proper management and conservation of fish resources (5,113). VNN is one of the emerging serious viral infections with mortalities up to 100% in fish larvae and juveniles leading to high economic loss. The disease can spread in wide geographical areas with a wide range of cultured and wild fish species susceptible to it. Vertical and horizontal transmission, a wide range of susceptible hosts, high resistance of the virus may contribute to the spread of the disease.

Also, stress such as insufficient food, bad water quality, overcrowding and repeated spawning are involved in VNN outbreaks (112). Evidence of VNN has been isolated from gonads and brain homogenates in some wild species from marine protected areas of southeast Italy (5).

It has been mentioned that a pathogen may be introduced through wild species, global warming, protective barriers, transport of animals, exchange of pathogens between wild and farmed fish and food an important vehicle of pathogens (5,113). Larval and juvenile stages of sensitive species to nodaviriosis have typical lesions in the central nervous system and retina.

The virus can multiply in the gonads, liver, stomach, kidney and intestine. The virus can also be transmitted vertically by eggs or sperms and horizontally by contaminated water, human activity, and vehicles.

The causative agents of VNN resist pH ranging from 2 to 9 and seawater thereby increasing horizontal transmission (5,105).

Infected wild fish with no clinical signs can show pathological changes under stress condition. The virus can transfer between white winter flounder (*Pseudopleuronectes americanus*) and sea caged halibut (*Hippoglossus hippoglossus*) or cod (*Gadus morhua*) (114), and from wild marine fish to surrounding mariculture areas.

Asymptomatic fish as reservoirs of infection might spread the pathogen as virus carriers. Affected wild fish in the population are rapidly preyed making it difficult to observe the disease (5).

The virus not only damages the nervous system but also, leads to failure in reproduction, reduces hatching rates and results in high larval mortality (5). Regarding the widespread of this virus and the possible consequences of asymptomatic forms, it is necessary to conduct disease surveillance and monitoring programs in all intensive aquaculture areas (5).

Official reports of the disease have been from many areas including Asia (Iran, India, Indonesia, Japan, Korea, Malaysia, Philippines, Thailand, Vietnam), Oceania (Australia, Tahiti), Mediterranean (France, Greece, Occupied Palestine, Italy, Malta, Portugal, Spain, Tunisia), England, Norway, Caribbean, and North America (Canada, USA) (66).

Each of the wide range of carriers and vertical transmission are a challenge and effective treatment is not available that makes it necessary to implement essential management and tight biosecurity and preventive measures (112).

Some factors such as water quality especially, water temperature, species, age, life stages, inappropriate handling and food are considered as risk factors for VNN infection. Eradication of VNN is difficult due to the role of environmental conditions in viral growth and spreading and resistance of VNN in water environments (8, 48). Different kinds of fish such as cold-water fish, warm water fish, ornamental fish and sturgeon fish can be infected by VNN that makes it one of the most serious threats for mariculture in the Persian Gulf and Oman Sea of Iran in the future (8).

Exclusion of virus-carrying animals, elimination of infected spawners, disinfection of

fertilized eggs using ozone, vaccination of brood fish, screening of new viral reservoirs, reducing environmental and anthropogenic activities, good health management, proper biosecurity measures and preventive actions in both open environments and cultured facilities, ozonation of water, decreasing stress factors and further research to provide an appropriate vaccine are recommended to reduce losses related to VNN.

Conclusion

In the last decade, VNN infection has been reported among cultured and marine fish worldwide. So far, morbidity and sensitivity of more than 50 fish species of wild marine or reared fishes to VNN have been reported since 1986 (96). The clinical signs of VNN in larvae and juveniles are characterized by a variety of neurological abnormalities, such as erratic swimming behavior (spiral, whirling or belly-up at rest), darkening of the body, enlarged swimbladder and massive mortality (66).

In the last decade, VNN was reported in all continents except Africa; but recently, some official outbreaks have been reported in wild groupers in North beaches of some African countries such as Tunisia, Algeria, Libya, and Senegal.

This infectious viral disease can spread in marine waters or freshwater of tropical, moderate, and cold areas in fishes that can live in warm or cold waters, and also in ornamental and marine fish. It may be concluded that VNN can be considered the main reason for morbidity and mortality of some important marine fish in the world. So, all aspects of VNN as the most important catastrophic emerging viral disease in marine aquaculture should be discussed (96).

Therefore, developing new rapid diagnostic tools for quick detection of viral carriers or health apparently, monitoring and surveillance programs, effective vaccines, control, prevention and eradication should be considered globally in a comprehensive program.

Acknowledgements

All the authors acknowledge the support from their respective institutions and universities.

Conflict of Interest

The authors declare that they have no conflict of interest.

References

1. Costa JZ, Thompson KD. Understanding the interaction between betanodavirus and its host for the development of prophylactic measures for viral encephalopathy and retinopathy. *Fish Shellfish Immunol.* 2016;53:35-49.
2. Chang JS, Chi SC. GHSC70 is involved in the cellular entry of nervous necrosis virus. *J Virol.* 2015;89:61-70.
3. OIE, Manual of Diagnostic Tests for Aquatic Animals. Chapter 2.3.12: Viral encephalopathy and retinopathy, 2017.
4. Panzarin V, Patamello P, Mori A, Rampazzo E, Cappellozza E, Bovo G. Development and validation of a real time TaqMan PCR assay for the detection of betanodavirus in clinical specimens. *Archives of V and intestine. Virology.* 2010;155, 1193-1203.
5. Terlizzi A, Tedesco P, and Patarnello P. Spread of pathogens from Marine cage aquaculture – A potential threat for wild fish assemblages under protection regimes? *Health Environ Aquac.* 2012; 403-414.
6. Doan QK, Vandeputte M, Chatain B, Morin T, Allal F. Viral encephalopathy and retinopathy in aquaculture: a review. *J fish Dis.* 2017;40(5):717-742.
7. Toffan A, Pascoli F, Pretto T, Panzarin V, Abbadi M, Buratin A. Viral Nervous Necrosis in gilthead sea bream (*Sparus aurata*) caused by reassortant betanodavirus RGNNV/SJNNV: an emerging threat for Mediterranean aquaculture. *Sci Rep.* 2017;7:46755:1-12.
8. Zorriehzahra MJ, Adel M, Dadar M, Ullah S, Ghasemi M. Viral Nervous Necrosis (VNN) an emerging disease caused by Nodaviridae in aquatic hosts: Diagnosis, control and prevention: A review. *Iran J Fish Sci.* 2019:1-18.
9. Tan C, Huang B, Chang SF, Ngoh GH, Munday, B, Chen SC. Determination of the complete nucleotide sequences of RNA1 and RNA2 from greasy grouper (*Epinephelus tauvina*) nervous necrosis virus, Singapore strain. *J Gen Virol.* 2001;82: 647-653.
10. Yong CY, Yeap SK, Omar AR, and Tan WS. Advances in the study of nodavirus. *Peer Rev J.* 2017;5:e3841.
11. Thie'ry R, Cozien J, de Boisse'son C, Kerbart-Boscher S, Ne'vearez L. Genomic classification of new betanodavirus. Isolates by phylogenetic analysis of the coat protein gene suggests a low host-fish species specificity. *J Gen Virol.* 2004;85, 3079-3087.
12. Nishizawa T, Furuhashi M, Nagai T, Nakai T, Muroga K. Genomic classification of fish nodaviruses by molecular phylogenetic analysis of the coat protein gene. *Appl Environ Microbiol.* 1997; 63:1633-1636.
13. Shetty M, Maiti B, Santhosh KS, Venugopal MN, Karunasagar I. Betanodavirus of marine and freshwater fish: distribution, genomic organization, diagnosis and control measures. *Indian J Virol.* 2012;23:123.
14. Zorriehzahra MJ, Nazari A, Ghasemi M, Ghiasi M, Karsidani SH, Bovo G. Vacuolating encephalopathy and retinopathy associated with a nodavirus-like agent: a probable cause of mass mortality of wild Golden grey mullet (*Liza aurata*) and Sharp nose grey mullet (*Liza saliens*) in Iranian waters of the Caspian Sea. *Virus Dis.* 2014;25:430-436.
15. Nazari A, Hassan MD, Bovo G, Zorriehzahra MJ, Azmi T. Pathogenicity of viral nervous necrosis virus for Guppy fish, *Poecilia reticulata*. *Iran J Fish Sci.* 2014;13(1):168-177.
16. Ghiasi M, Binaii M, Ghasemi M, Fazli H, Zorriehzahra MJ. Haematobiochemical disorders associated with nodavirus like-agent in adult leaping mullet *Liza saliens* (Risso, 1810) in the Caspian Sea. *Virus Dis.* 2016;27:12-18.
17. Sethi SN, Vinod K, Rudhramurty N, Kokane MR, Pattnaik P. Detection of betanodavirus in wild caught fry milk fish *Chanos chanos* (Lacepedes 1803). *Indian J Geomarine Sci.* 2018;47(08):1620-1624.
18. Ransangan J, Manin BO. Mass mortality of hatchery-produced larvae of Asian sea bass, *Lates calcarifer* (Bloch), associated with nervous necrosis in Sabah, Malaysia. *Vet Microbiol.* 2010; 145:153-7
19. Parameswaran V, Kumar SR, Hameed Ahmed AS. A fish nodavirus associated with mass mortality in hatchery-reared Asian sea bass, *Lates calcarifer*. *Aquaculture.* 2008;275:366-9
20. Oh MJ, Jung SJ, Kim SR, Rajendran KV, Kim YJ, Choi TJ, et al. A fish nodavirus associated with mass mortality in hatchery-reared red drum, *Sciaenops ocellatus*. *Aquaculture.* 2002;211:1-7.

21. Bovo G, Gustinelli A, Quaglio F, Gobbo F, Panzarin V, Fusaro A. Viral encephalopathy and retinopathy outbreak in freshwater fish farmed in Italy. *Dis Aquat Organ.* 2011;96:45-54.
22. Ransangan J, Manin BO, Abdullah A, Roli Z, Sharudin EF. Betanodavirus infection in golden pompano, *Trachinotus blochii*, fingerlings cultured in deep-sea cage culture facility in Langkawi, Malaysia. *Aquaculture.* 2011;315:327-334.
23. Hegde A, Teh HC, Lam TJ, Sin YM. Nodavirus infection in freshwater ornamental fish, guppy, *Poecilia reticulata*- comparative characterization and pathogenicity studies. *Arch Virol.* 2003;148, 575-586.
24. Jaramillo D, Hick P, Dyrting K, Anderson I, Whittington RJ. Surveillance for nervous necrosis virus-specific antibodies in barramundi *Lates calcarifer* in Australian hatcheries. *Dis Aquat Organ.* 2017;124:1-10.
25. Low CFC, SyarulNataqain B, Chee HY, Rozaini MZH, Najiah M. Betanodavirus: Dissection of the viral life cycle. *J Fish Dis.* 2017; 40:1-8.
26. Nazari A, Hassan MD, Bovo G, Zorriehzahra MJ, Azmi TI, Arshad SS. Pathogenicity of viral nervous necrosis virus for Guppy fish, *Poecilia reticulata*. *Iran J Fish Sci.* 2014;13 (1):168-177.
27. Viral Zone. WWW.expasy.org/viralzone, SIB Swiss Institute of Bioinformatic, 2020.
28. Chen NC, Yoshimura M, Guan HH, Wang TY, Misumi Y, Lin CC. Crystal Structures of a Piscine Betanodavirus: Mechanisms of Capsid Assembly and Viral Infection. *PLoS Pathog.* 2015;11(10): e1005203.
29. Nuñez-Ortiz N, Pascoli F, Picchietti S, Buonocore F, Bernini C, Toson M. A formalin-inactivated immunogen against viral encephalopathy and retinopathy (VER) disease in European sea bass (*Dicentrarchus labrax*): immunological and protection effects. *Vet Res.* 2016;47:89.
30. Baud M, Cabon J, Salomoni A, Toffan A, Panzarin V, Bigarré L. First generic one step real-time Taqman RT-PCR targeting the RNA1 of betanodaviruses. *J Virol Methods.* 2015;211:1-7.
31. Martinez DJ. Epidemiology and pathogenesis of Nervous Necrosis Virus. A thesis submitted in fulfilment of the requirements for the degree of Doctor of Philosophy. Farm Animal and Veterinary Public Health, Faculty of Veterinary Science, University of Sydney, 2015.
32. Gomez DK, Lim DJ, Baeck GW, Youn HJ, Shin NS, Youn HY. Detection of betanodaviruses in apparently healthy aquarium fishes and invertebrates. *Vet Sci.* 2006;7(4):369-374.
33. Furusawa R, Okinaka Y, Uematsu K, Nakai T. Screening of freshwater fish species for their susceptibility to a betanodavirus. *Dis Aquat Organ.* 2007;77:119-125.
34. Binesh C. Mortality due to viral nervous necrosis in zebrafish *Danio rerio* and goldfish *Carassius auratus*. *Dis Aquat Organ.* 2013;104: 257-260.
35. Maltese C, Bovo G. Monografie. Viral encephalopathy and retinopathy/ Encefalopatia e retinopatiavirale. *Ittiopatologia.* 2007;4:93-146.
36. Vendramin N, Patarnello P, Toffan A, Panzarin V, Cappelozza E, Tedesco P. Viral Encephalopathy and Retinopathy in groupers (*Epinephelus* spp.) in southern Italy: a threat for wild endangered species? *BMC Vet Res.* 2013;9:20.
37. Yoshikosh, Inoue K. Viral nervous necrosis in hatchery-reared larvae and juveniles of Japanese parrotfish *Oplegnathus fasciatus* (Temminck & Schlegel). *J Fish Dis.* 1990;13:69-77.
38. Sohn SG, Park MA, Lee SD, Chun SK. Studies on the mass mortality of the cultured grouper. *J Fish Pathol.* 1991;4:87-94.
39. Bandín I, Dopazo CP. Host range, host specificity and hypothesized host shift events among viruses of lower vertebrates. *Vet Res.* 2011; 42(1):67.
40. Lin CS, Lu MW, Tang L, Liu W, Chao CB, Lin CJ. Characterization of virus-like particles assembled in a combinant baculovirus system expressing the capsid protein of fish nodavirus. *Virology.* 2001;290:50-58.
41. Chi SC, Lee KW, Hwang SJ. Investigation of host range of fish nodavirus in Taiwan. In *Proceeding of the Tenth International Conference of the European Association of Fish Pathologists.* 21st edition. Edited by The European Association of Fish Pathologists. Aberdeen, Scotland: Albion Press, 2001; 40:49.
42. Hsiao-Che K, Ting-Yu W, Peng-Peng C, Young-Mao C, Hui-Ching C, Tzong-Yueh C. Real-time quantitative PCR assay for monitoring of nervous necrosis virus infection in grouper aquaculture. *Clin Microbiol.* 2011;49:1090-1096.
43. Marino G, Azzurro E. Nodavirus in dusky grouper *Epinephelus marginatus* (Lowe 1834) of the Natural Marine Reserve of Ustica, South Tyrrhenian Sea. *Biol Mar Mediterr.* 2001;8:837-841.
44. Maltese C, Antonetti P, Quartesan R, Ormelli S, Borghesan F, Manfrin A. Isolation of viral encephalopathy and retinopathy virus (VERV) from wild marine fish species in the Mediterranean Sea. In: *Proceeding of the Twelfth International Conference Diseases of Fish and Shellfish, European Association of Fish Pathologists, Copenhagen.* Edited by The European Association

Impact of Viral Nervous Necrosis (VNN) Disease as a New Threat to Global Fisheries and Aquaculture Development- A Review

of Fish Pathologists. Aberdeen: Albion Press, 2005; 8–19.

45. Nishi S, Yamashita H, Kawato Y, Nakai T. Cell Culture Isolation of Piscine Nodavirus (Betanodavirus) in Fish-Rearing Seawater. *Appl Environ Microbiol.* 2016;82(8):2537-2542.

46. Azad IS, Shekhar MS, Thirunavukkarasu AR, Poornima M, Kailasam M, Rajan JJS. Nodavirus infection causes mass mortalities in hatchery produced larvae of Asian seabass, *Lates calcarifer*, Bloch: first report from India. *Dis Aquat Organ.* 2005;63:113-118.

47. Souto S, Oliveira JG, Bandín I. Influence of temperature on Betanodavirus infection in Senegalese sole (*Solea senegalensis*). *Vet Microbiol.* 2015;179:162–167.

48. Juniar, E., Kurnia, K., and Sumiarto, B. Risk factors of a viral nervous necrosis disease in grouper (*Epinephelus* spp.) cultured in Bintan district, Indonesia. *VetWorld.* 2018;11:1558-1563.

49. Toffan A, Panzarin V, Toson M, Cecchetti K, Pascoli F. Water temperature affects pathogenicity of different betanodavirus genotypes in experimentally challenged *Dicentrarchus labrax*. *Dis Aquat Organ.* 2016;119:231–238.

50. Oliveira JG, Souto S, Dopazo CP, Bandín I. Isolation of betanodavirus from farmed turbot *Psetta maxima* showing no signs of viral encephalopathy and retinopathy. *Aquaculture.* 2013;406:125–130.

51. Bloch, B., Gravningen, K., and Larsen, J.L. Encephalomyelitis among turbot associated with apicomavirus-like agent. *Dis Aquat Organ.* 1991;10:65–70.

52. Gomez DK, Sato J, Mushiake K, Isshiki T, Okinaka Y, Nakai T. PCR-based detection of betanodaviruses from cultured and wild marine fish with no clinical signs. *J Fish Dis.* 2004;27:603–608.

53. Curtis PA, Drawbridge M, Iwamoto T, Nakai T, Hedrick RP, Gendron AP. Nodavirus infection of juvenile white sea-bass (*Atracto scionnobilis*) cultured in southern California: first record of viral nervous necrosis (VNN) in North America. *J Fish Dis.* 2001;24:263–271.

54. Breuil G, Bonamib JR, Pepin JF, Pichot Y. Viral infection (picorna-like virus) associated with mass mortalities in hatchery-reared sea-bass (*Dicentrar chuslabrax*) larvae and juveniles. *Aquaculture.* 1991;97:109–116.

55. Mori K, Mangyoku T, Iwamoto T, Arimoto M, Tanaka S, Nakai T. Serological relationships among genotypic variants of betanodavirus. *Dis Aquat Organ.* 2003;57:19–26.

56. Cutrim JM, Dopazo CP, Thiery R, Leao P, Oliveira JG, Barja JL. Emergence of pathogenic betanodaviruses belonging to the SJNNV genogroup in farmed fish species from the Iberian Peninsula. *J Fish Dis.* 2007;30:225–232.

57. NaveenKumar S, Hassan MAA, Mahmoud M, Al-Ansari A, Al-Shwared WK. Betanodavirus infection in reared marine fishes along the Arabian Gulf. *Springer, Aquac Int.* 2017;56(6).

58. Sugaya T, Mori K, Nishioka T, Masuma S, Oka M, Mushiake K. Genetic heterogeneity of betanodaviruses in juvenile production trials of Pacific blue fin tuna, *Thunnus orientalis* (Temminck & Schlegel). *J Fish Dis.* 2009;32:815–823.

59. Chi SC, Shieh JR, Lin SJ. Genetic and antigenic analysis of betanodaviruses isolated from aquatic organisms in Taiwan. *Dis Aquat Organ.* 2003;55:221–228.

60. Mori K, Nakai T, Muroga K, Arimoto M, Mushiake K, Furusawa I. Properties of a new virus belonging to nodaviridae found in larval striped jack (*Pseudocaranx dentex*) with nervous necrosis. *Virology.* 1992;187:368–371.

61. Yuasa K, Koesharyani I, Mahardika K. Effect of high water temperature on betanodavirus infection of fingerling Humpback grouper (*Cromi-leptes altivelis*). *Fish Pathol.* 2007;42:219–221.

62. Chi SC, Hu WW, Lo BJ. Establishment and characterization of a continuous cell line (GF-1) derived from grouper, *Epinephelus coioides* (Hamilton): a cell line susceptible to grouper nervous necrosis virus (GNNV). *J Fish Dis.* 1999;22:173–182.

63. Fukuda Y, Nguyen HD, Furuhashi M, Nakai T. Mass mortality of cultured seven band grouper, *Epinephelus septemfasciatus*, associated with viral nervous necrosis. *Fish Pathol.* 1996;31:165–70.

64. Hegde A, Chen CL, Qin QW, Lam TJ, Sin YM. Characterization, pathogenicity and neutralization studies of a nervous necrosis virus isolated from grouper, *Epinephelus tauvina*, in Singapore. *Aquaculture.* 2002;213:55–72.

65. Lai YS, Chiu HC, Murali S, Guo IC, Chen SC, Fang K. Propagation of yellow grouper nervous necrosis virus (YGNNV) in a new nodavirus susceptible cell line from yellow grouper, *Epinephelus awoara* (Temminck & Schlegel), brain tissue. *J Fish Dis.* 2001;24:299–309.

66. Munday BL, Kwang J, Moody N. Betanodavirus infections of teleost fish: a review. *J Fish Dis.* 2002;25:127-142.

67. Nishizawa T, Mori K, Furuhashi M, Nakai T, Furusawa I, Muroga K. Comparison of the coat protein genes of five fish nodaviruses, the causative

- agents of viral nervous necrosis in marine fish. *J Gen Virol.* 1995;76:1563–1569.
68. Grotmol S, Totland GK, Thorud K, Hjeltnes BK. Vacuolating encephalopathy and retinopathy associated with a nodavirus-like agent: a probable cause of mass mortality of cultured larval and juvenile Atlantic halibut *Hippoglossus hippoglossus*. *Dis Aquat Organ.* 1997;29:85–97.
69. Johansen R, Sommerset I, Tørud B, Korsnes K, Hjortaaas MJ, Nilsen F. Characterization of nodavirus and viral encephalopathy and retinopathy in farmed turbot, *Scophthalmus maximus* (L.). *J Fish Dis.* 2004;27:591–601.
70. Johnson SC, Sperker SA, Leggiadro CT, Groman DB, Griffiths SG, Ritchie R. Identification and characterization of a piscine neuropathy and nodavirus from juvenile Atlantic cod from the Atlantic coast of North America. *J Aquat Anim Health.* 2002;14(2):124–133.
71. Gagne N, Johnson SC, Cook-Versloot M, MacKinnon AM, Olivier G. Molecular detection and characterization of nodavirus in several marine fish species from the northeastern Atlantic. *Dis Aquat Organ.* 2004;62:181–189.
72. Tang KFJ, Carlos RP, Redman RM, Lightner DV. Development of in situ hybridization and RT-PCR assay for the detection of a nodavirus (PvNV) that causes muscle necrosis in *Penaeus vannamei*. *Dis Aquat Organ.* 2007;75:183–190.
73. Lu MW, Chao YM, Guo TC, Santi N, Evensen, O, Kasani SK. The interferon response is involved in nervous necrosis virus acute and persistent infection in zebrafish infection model. *Mol Immunol.* 2008;45:1146–1152.
74. Vendramin N, Padros F, Pretto T, Cappellozza, E, Panzarin V, Bovo G. Viral encephalopathy and retinopathy outbreak in restocking facilities of the endangered freshwater species, *Salaria fluviatilis* (Asso). *J Fish Dis.* 2012;35:867–871.
75. Furusawa R, Okinaka Y, Nakai T. Betanodavirus infection in the freshwater model fish medaka (*Oryzias latipes*). *J Gen Virol.* 2006;87:2333–2339.
76. Giacopello C, Foti M, Bottari T, Fisichella V, and Barbera G. Detection of viral encephalopathy and retinopathy virus (VERV) in wild marine fish species of the South Tyrrhenian Sea (Central Mediterranean). *J Fish Dis.* 2013;36:819–821.
77. Ciulli S, Galletti E, Grodzki M, Alessi A, Battilani M, Prospero S. Isolation and genetic characterization of Betanodavirus from wild marine fish from the Adriatic Sea. *Vet Res Commun.* 2007;31:221–224.
78. Gomez DK, Baeck GW, Kim JH, Choresca CH, Park SC. Molecular detection of betanodaviruses from apparently healthy wild marine invertebrates. *J Invertebr Pathol.* 2008; 97:197–202.
79. Bigarre L, Cabon J, Baud M, Heimann M, Body A, Lieffrig F, Castric J. Outbreak of betanodavirus infection in tilapia (*Oreochromis niloticus* L.), in fresh water. *J Fish Dis.* 2009;32:667–673.
80. Athanassopoulou F, Billinis C, Prapas T. Important disease conditions of newly cultured species in intensive freshwater farms in Greece: first incidence of nodavirus infection in *Acipenser* sp. *Dis Aquat Organ.* 2004;60:247–252.
81. Bonami JR, Widada SJ. Viral diseases of the giant fresh water prawn *Macrobrachium rosenbergii*: a review. *J invertebr Pathol.* 2011;106:131–142.
82. Mladineo I. The immunohistochemical study of nodavirus changes in larval, juvenile and adult sea bass tissue. *J Appl Ichthyol.* 2003;19:366–370.
83. Banu G, Mori K, Arimoto M, Chowdhury M, Nakai T. Portal entry and progression of betanodaviruses causing viral nervous necrosis in seven band grouper *Ephinephelus septemfasciatus*. *Bangladesh J Vet Med.* 2004;2:83–87.
84. Tanaka S, Takagi M, Miyazaki T. Histopathological studies on viral nervous necrosis of seven-band grouper, *Epinephelus septemfasciatus* Thunberg, at the grow-out stage. *J Fish Dis.* 2004;27: 385–399.
85. Pirarat N, Ponpornpisit A, Traithong T, Nakai, T, Katagiri T. Nodavirus associated with pathological changes in adult spotted coral groupers (*Plectropomus maculatus*) in Thailand with viral nervous necrosis. *Res Vet Sci.* 2009;87:97–101.
86. Grotmol S, Bergh Ø, Totland GK. Transmission of viral encephalopathy and retinopathy (VER) to yolk-sac larvae of the Atlantic halibut *Hippoglossus hippoglossus*: occurrence of nodavirus in various organs and a possible route of infection. *Dis Aquat Organ.* 1999;36(2):95–106.
87. Nguyen HD, Nakai T, Muroga, K. Progression of striped jack nervous necrosis virus (SJNNV) infection in naturally and experimentally infected striped jack *Pseudocaranx dentex* larvae. *Dis Aquat Organ.* 1996;24:99–105.
88. Nguyen HD, Mushiake K, Nakai T, Muroga K. Tissue distribution of striped jack nervous necrosis virus (SJNNV) in adult striped jack. *Dis Aquat Organ.* 1997;28:87–91.
89. Johansen R, Amundsen M, Dannevig BH, Sommer AI. Acute and persistent experimental nodavirus infection in spotted wolf fish *Anarhichas minor*. *Dis Aquat Organ.* 2003;57:35–41.
90. Grove S, Faller R, Soleim KB, Dannevig BH. Absolute quantitation of RNA by a competitive

real-time RT-PCR method using piscine nodavirus as a model. *J Virol Methods*, 2006;132:104–112.

91. Korsnes, K., Karlsbakk, E., Devold, M., Nerland, A.H., and Nylund, A. Tissue tropism of nervous necrosis virus (NNV) in Atlantic cod, *Gadus morhua* L., after intraperitoneal challenge with a virus isolate from diseased Atlantic halibut, *Hippoglossus hippoglossus* L. *J Fish Dis*. 2009;32:655–665.

92. Lopez-Jimena B, Alonso MDC, Thompson KD, Adams A, Infante C. Tissue distribution of red spotted grouper nervous necrosis virus (RGNNV) genome in experimentally infected juvenile European seabass (*Dicentrarchus labrax*). *Vet Microbiol*. 2011;154:86–95.

93. Mazelet, L., Dietrich, J., and Rolland, J.L. New RT-qPCR assay for viral nervous necrosis virus detection in sea bass, *Dicentrarchus labrax* (L.): application and limits for hatcheries sanitary control. *Fish Shellfish Immunol*. 2011;30:27–32.

94. Grove, S., Johansen, R., Dannevig, B.H., Reitan, L.J., and Ranheim T. Experimental infection of Atlantic halibut *Hippoglossus hippoglossus* with nodavirus: tissue distribution and immune response. *Dis Aquat Organ*. 2003;53:211–221.

95. Azad, I.S., Jithendran, K.P., and Shekhar, M.S. Immunolocalisation of nervous necrosis virus indicates vertical transmission in hatchery produced Asian sea bass (*Lates calcarifer* Bloch)—a case study. *Aquaculture*. 2006;255:39–47.

96. Zorriehzahra, M.J. Viral Nervous Necrosis Disease. In *Emerging and Reemerging Viral Pathogens*, Academic Press, 2020; pp. 673-703.

97. Munday, B.L., Langdon, J.S., Hyatt, A., and Humphrey J.D. Mass mortality associated with a viral-induced vacuolating encephalopathy and retinopathy of larva and juvenile barramundi, *Lates calcarifer* (Bloch). *Aquaculture*. 1992;103:197-211.

98. Grotmol S, Totland GK, Kvellestad A, Fjell K, Olsen AB. Mass mortality of larval and juvenile hatchery-reared halibut (*Hippoglossus hippoglossus* L.) associated with the presence of virus like particles in the central nervous system and retina. *Bull Eur Assoc Fish Pathol*. 1995;15:176-180.

99. Comps, M, Raymond JC. Virus-like particles in the retina of the seabream, *Sparus aurata*. *Bull of Eur Assoc of Fish Pathol*. 1996;16:161-163.

100. Zorriehzahra MEJ, Nakai T, Gomez D, Chi CS, Sharifpour I, Hassan HMD. Mortality of wild golden grey mullet (*Liza auratus*) in Iranian waters of the Caspian Sea associated with viral nervous necrosis-Like agent. *Iran J Fish Sci*. 2005;4(2):43-58.

101. Nopadon P, Aranya P, Tipaporn T, Toshihiro N, Takayuki K, Masashi M. Nodavirus associated with pathological changes in adult spotted coral groupers (*Plectropomus maculatus*) in Thailand with viral nervous necrosis. *Res Vet Sci*. 2009;87:97-101.

102. Hazreen-Nita M, Azila A, Mukai Y, Firdaus-Nawi M, Nur-Nazifah M. A review of betanodavirus vaccination as preventive strategy to viral nervous necrosis (VNN) disease in grouper. *Aquac Int*. 2019;27(5):1565-1577.

103. Glazebrook JS, Heasman MP, De Beer SW. Picorna-like viral particles associated with mass mortalities in larval barramundi, *Lates calcarifer* (Bloch). *J Fish Dis*. 1990;13:245-249.

104. Le Breton A, Grisez L, Sweetman J, Ollevier, F. Viral nervous necrosis (VNN) associated with mass mortalities in cage-reared sea bass, *Dicentrarchus labrax* (L.). *J Fish Dis*. 1997;20:145-151.

105. Nakai T, Sugaya T, Nishioka T, Mushiaki K, Yamashita H. Current knowledge on viral nervous necrosis (VNN) and its causative betanodaviruses. *J Aquac*. 2009;61(3):198-207.

106. Starkey WG, Millar RM, Jenkins ME, Ireland JH, Muir KF, Richards RH. Detection of piscine nodavirus by real-time nucleic acid sequence based amplification (NASBA). *Dis Aquat Organ*. 2004;59:93–100.

107. Munday BL, Nakai T. Nodaviruses as pathogens in larval and juvenile marine finfish. *World J Microbiol Biotechnol*. 1997;13(4):375-381.

108. Su Y, Xu H, Ma H, Feng J, Wen W, Guo Z. Dynamic distribution and tissue tropism of nervous necrosis virus in juvenile pompano (*Trachinotus ovatus*) during early stages of infection, *Aquaculture*. 2015;440:25-31.

109. Zorriehzahra MJ, Ghasemi M, Ghiasi M, et al. Study of Viral Nervous Necrosis (VNN) in Caspian Sea grey mullet *Liza auratus* and the evaluation of its infection and a transition probability to other fish (sturgeon, *Rutilus frisii* and cultural fish) in Iran. Final report of a national research project. *Iran Fish Res Organ*. 2013;186P.

110. Pavoletti E, Prearo M, Ghittino M, Ghittino C. Cases of viral encephalo-retinopathy in shy drum (*Umbrina cirrosa*), with description of clinic symptomatology and anatomo-histopathological features. *Bulletin, Ital Soc Fish Pathol*. 1998;23:24-33.

111. Hassantabar F, Firouzbakhsh F, Zorriehzahra MJ, Thompson K. The introduction of a new modified Nested RT-PCR molecular technique for rapid diagnosis of Viral Nervous Necrosis (VNN). *Iran J Fish Sci*. 2019;27(6):115-125.

112. Jithendran KP, Ezhil Praveena P, Bhuvanewari T. Viral Nervous Necrosis: A challenge to fin-fish aquaculture. Basic and clinical virology: Student book, 2017:6p.
113. Gozlan RE, St-Hilaire S, Feist SW. Biodiversity: disease threat to European fish. Nature. 2005;435:1046.
114. Barker. DE, MacKinnon AM, Boston L, Burt MD, Cone DK, Speare DJ. First report of piscine nodavirus infecting wild winter flounder *Pleuronectes americanus* in Passamaquoddy Bay, New Brunswick, Canada. Dis Aquat Organ. 2002;49(2): 99-105.