

Original Article

Molecular and Histopathological Characterization of Inclusion Body Hepatitis (IBH) in Broiler Chickens in Isfahan Province

Ghorani M¹, Ghalyanchi Langeroudi A^{2*}, Khordadmehr M¹, Hojabr Rajeoni A²

1. Department of Pathobiology, Faculty of Veterinary Medicine, Tabriz, University of Tabriz, Iran

2. Department of Microbiology and Immunology, Faculty of Veterinary Medicine, University of Tehran, Tehran, Iran

Abstract

Background and Aims: The Inclusion Body Hepatitis disease (IBH) is one of the prevalent illnesses in our country these days and reported from different regions of Iran. In addition to its fatality, the importance of this disease is disturbing the vaccination program in poultry, especially broiler chickens, against other diseases like infectious bursal disease (IBD) and Newcastle disease (ND). This study aimed to determine the molecular phylogenetic and histopathological analysis of IBH in the Kashan region (Isfahan province).

Materials and Methods: Liver samples collected from infected chickens examined using PCR and histopathological procedure. Phylogenetic analysis was done by drawing a phylogenetic tree.

Results: All samples were positive with PCR. Also, the samples were investigated by histopathological procedure, and congestion, hemorrhage, focal necrosis, and intranuclear inclusion bodies in the hepatocytes were observed.

Conclusion: According to the phylogenetic analysis, the Iranian isolate in this research was similar to European countries' isolates. Other aspects of IBH disease like pathogenesis and epidemiology should be investigated.

Keywords: Fowl adenovirus; Histopathology; Broiler chickens; Phylogenetic analysis; PCR

Introduction

Inclusion Body Hepatitis (IBH) caused by fowl adenovirus (FAdV) belongs to the family Adenoviridae, and the genus Aviadenovirus is divided into five species (A to E) and 12 serotypes. Adenovirus infections are widespread among domestic birds as well as wild birds. These viruses often do not cause the clinical signs of primary infection in many of these birds and act as opportunistic infections (1). Inclusion Body Hepatitis (IBH) was first identified in the United States in 1963 and has since spread worldwide (2). Since then, the disease has been reported from around the world (1).

The disease presents with a wide range of clinical symptoms, from asymptomatic to high

mortality. Liver damage, pericardial effusion syndrome (HPS), and secondary infections due to suppression of the immune system are among these clinical symptoms. Multiple adenovirus strains destroy lymphocytes in the bursa of Fabricius, thymus, and spleen, leading to suppressing the immune system. IBH usually occurs in broilers between 3-7 weeks but has also been reported in seven-day-old chickens up to 20 weeks. (3). Typically, the disease is discerned with a mortality rate of between 2-40% in chickens. High mortality is commonly seen in chickens less than three weeks old. Due to the pathogenicity of the virus, in secondary co-infection, the mortality rate has been reported up to 80%. In general, the maximum mortality rate is between three and four days and decreases within nine to 14 days. Clinically, affected birds show lethargy, bunch together, fluffy feathers, and anorexia (4). At necropsy, disease lesions include swollen, pale, and fragile livers with foci of necrosis. Ecchymosis and bleeding may be

* Corresponding author:

Arash Ghalyanchi Langeroudi.

Email: arashghalyanchi@gmail.com.

seen in the liver and to a lesser extent in the legs and chest muscles. In most cases, the lesions are related to the liver.

Laboratory diagnosis of adenoviral infections, including IBH in birds, is based on histopathological findings and intranuclear inclusion bodies in hepatocytes (5).

Histopathological lesions include areas of focal necrosis and, in some hepatocytes, intranuclear inclusion bodies. Inclusion bodies can be eosinophilic, large, round, irregular in shape with a slight halo, or sometimes basophilic (6). Detection of antigens and viral particles using immunofluorescence tests and electron microscopy are other diagnostic methods (4).

Recently, the use of the PCR (polymerase chain reaction) technique has become widespread as a rapid and sensitive method for detecting avian adenoviruses. The molecular method, especially PCR, is used to identify and study virus species, strains, and serotypes. The Hexon gene is the most suitable option for molecular detection of this virus, and primers usually design for this gene in diagnostic molecular tests. The hexon gene is also used to determine the type, group, and subgroup of avian adenoviruses (7).

In this study, avian adenovirus type 1 was identified in a broiler farm located in Kashan city of Isfahan province by two molecular methods and histopathology. They were also evaluated phylogenetically.

Methods

Disease history: In a herd of 20,000 broiler chickens located in the Kashan region (Isfahan province) at the age of five days, the mortality reached its maximum (7.4%). These casualties lasted for three days and continued from the fourth day with a downward trend.

The chickens showed signs of lethargy and anorexia suddenly. At autopsy, the liver was enlarged, yellow, and sometimes pale (Fig. 1). Necrotic areas and sometimes petechiae were seen in the liver of some of the dead chickens. Since adenovirus vaccines are not used commercially in poultry in Iran, the adenovirus vaccine was not used in this case either.

Histopathological examination: Tissue samples were taken from the livers of slaughtered chickens, placed in 10% formalin for histopathological examination, and sent to the pathology laboratory.

In the pathology laboratory, tissue samples were routinely passed, and after preparing five μm sections of paraffin blocks, they were stained with hematoxylin and eosin and examined under a light microscope.

Molecular PCR test: The liver samples were combined and completely crushed in a sterile porcelain mortar. Then the samples were well mixed and homogenized by adding some physiological serum.

According to the manufacturer's protocol, viral DNA was extracted from the homogenized solution by SinaPure Viral kit (SinaClon). The primer sequence based on the hexon gene is shown in Table 1 (8).

After extracting the viral DNA, the following materials were used to make 25 μl PCR mixture: 4 μl dNTP (1.25 mM), One microliter of each of the forward and reverse primers (25 μM), 5 μl PCR buffer (5X), 1.25 U DNA polymerase enzyme (SinaClon), 2 μl Viral DNA, 2 μl MgCl_2 (25 mM) and nuclease-free water was added to a volume of 25 μl . Distilled water was used as a negative control sample. After the preparation of the PCR mixture, amplifications were done in T100™ Thermal Cycler (Bio-Rad, USA), according to the program mentioned in Table 2 (9). Repeat steps two to four for 40 cycles.

Bioinformatics and phylogenetic analysis: PCR products were purified using the Bioneer AccuPrep® Purification Kit (South Korea). Sequencing was performed with the ABI genetic analyzer in both forward and reversed directions.

Phylogenetic analysis was performed by the neighbor-joining method using MEGA software (version 7.0.21).

The nucleotide sequence of the hexon gene in our samples was examined and compared with the other FAdV strain sequences registered in the GenBank.

Results

The liver samples were positive for fowl adenovirus (FAdV) infection by PCR, and specific bands were observed by gel electrophoresis (Figure 2). At autopsy, the liver was enlarged, yellow, and sometimes pale (Fig. 1).

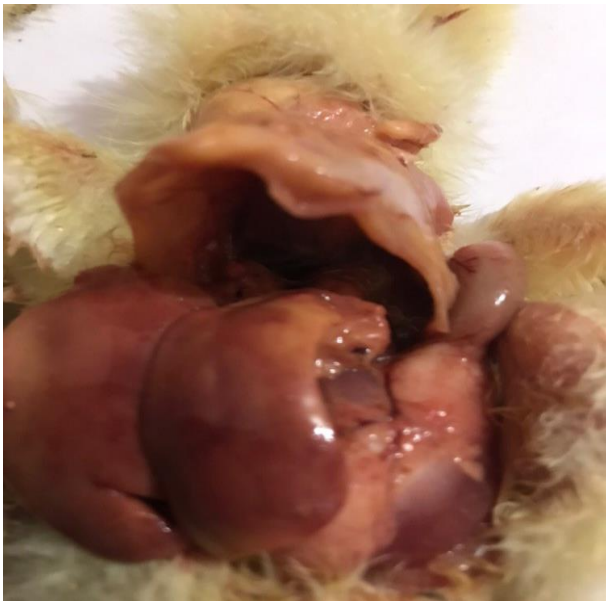

Fig. 1. Liver, five-days-old broiler chicken, IBH disease.

In histopathology tissue sections from the liver samples, hyperemia of the arteries and hepatic sinusoids, sinusoidal dilatation, necrosis, and focal hemorrhage were observed with the infiltration of inflammatory cells.

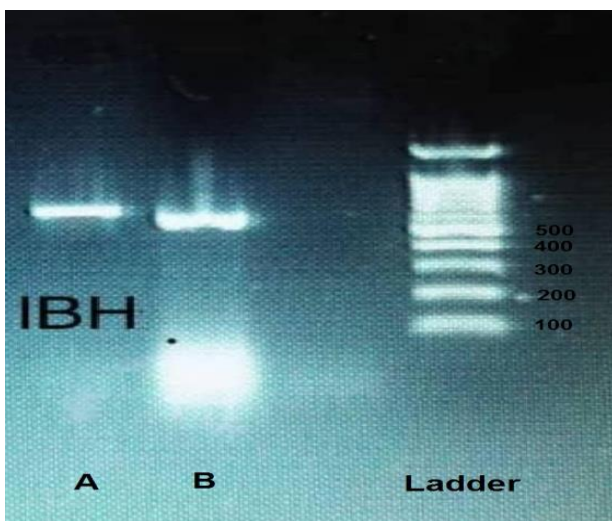


Fig. 2. PCR positive samples; A: positive control, B: positive sample tested, ladder 100 bp.

Inside the hepatocytes, there were basophilic intranuclear inclusion bodies of various sizes, confirming the diagnosis (Fig. 3). According to the phylogenetic analysis, the sequence of the strains studied in this study (Iran IBH), with strain KU647792.1 from Spain, LN907532.1, and LN907534.1 from Austria, JX257176.1 from Sweden, and the MG953207.1 from Hungary, are in the same group. The Iranian strain is almost 100% similar to the mentioned strains (Table 3). Spanish strains belong to serotypes 8b and 11.

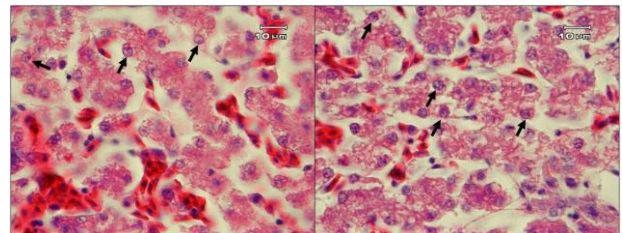


Fig. 3. Liver, broiler chicken, Inclusion Body Hepatitis. Sinusoidal congestion associated with basophilic intranuclear inclusion bodies (arrows) in the hepatocytes (H&E).

Discussion

Inclusion body hepatitis (IBH) is economically important in the poultry industry, especially broilers and broiler breeders in different countries (10). Although the prevalence of IBH is usually associated with serotypes 6, 7, and 8, the viruses associated with its prevalence in Iran are usually of serotype 11 based on the sequence of hexon gene PCR products (11). In ten-year research, Herdt et al. (2013) identified FAdV infections in 38 broiler herds from 310 diseased herds in Belgium (7). Based on hexon gene sequence analysis globally, the viral Inclusion body hepatitis infection belongs to serotypes 6, 7, and 8, but the predominant serotype of Iranian fowl adenovirus is serotype 11 (12).

In Iran, the first report of IBH identification and prevalence in broiler breeder flocks among three-week-old chickens with more than 30% mortality was associated with serotype 11 of Fowl adenovirus (11). Subsequently, Rahimi and Haghghi (2015) reported hepatitis similar to adenoviral hepatitis with high acute

mortality in a broiler flock in Kermanshah province.

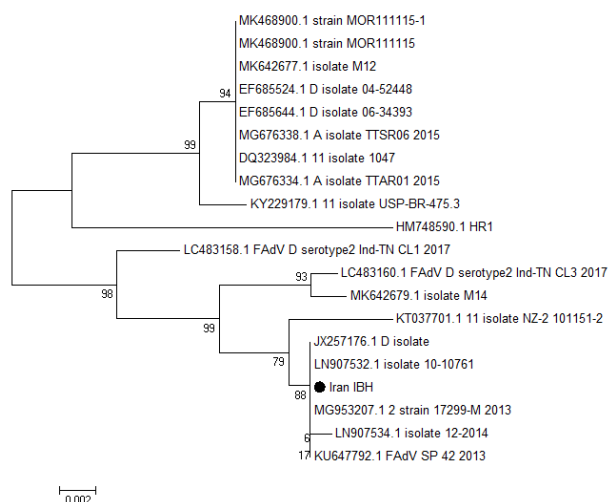


Fig. 4. Phylogenetic tree constructed based on hexogen gene with MEGA (7.0.21).

Their study was based on macroscopic lesions and histopathological findings (13).

Khodakaram Tafti *et al.* (2016) reported the prevalence of IBH in a broiler herd in Fars province with 10% mortality within a week. They stated that the disease could suppress the immune system, complicating other diseases, especially infectious bursal disease and Newcastle disease (14).

Primer size (bp)	Primer sequence (5'-3')	Primer name
596	ATGGGAGCSACCTAYTTCGACAT	Hex L1-s
596	AAATTGTCCCKRAANCCGATGTA	Hex L1-as

Tabib Ghaffari *et al.* (2017) molecularly examined 30 broiler herds in southwestern Iran and stated that genotype D and serotype 11 belong to Fowl adenoviruses in this region (15). Nateghi *et al.* (2014) reported that 10% of the samples collected and molecularly analyzed from northeastern Iran were positive for avian adenovirus (FADVs) infection and belonged to serotypes 8b, 2, and 11 (16). Also,

in another study, Morshed *et al.* (2017), by examining broiler flocks and broiler breeders, reported that the two serotypes 11 and 8b have the highest prevalence among Fowl adenoviruses in Iran. They were pathogenic to young chickens (17). Ghorbani *et al.* (2017) identified the IBH virus in poultry in southern Isfahan province by PCR (18).

Table 2. PCR Thermal cycle.

Time	Temperature (°C)	Step
2 min	94	1
20 s	94	2
20 s	56	3
30 s	72	4
10 min	72	5

The liver is the first organ to be affected by IBH, and histopathological procedures can easily confirm the presence of disease and observe intranuclear bodies in hepatocytes. The main histopathological findings of this study have been described in previous studies (11, 13).

Zadrauk *et al.* (2011) reported an IBH outbreak of 2.2% mortality in a meat herd in Slovenia (19). Fowl adenovirus serotype 8b and infectious bursal disease virus (IBD) and infectious bronchitis (IBV) virus were detected in this herd.

Metingfo *et al.* (2014) reported an outbreak of IBH and HPS belonging to group 1 avian adenovirus in Brazilian broiler herds (20).

The sensitivity of virus isolation is lower than that of molecular methods such as PCR on tissue. Virus isolation requires more than one passage to see the cytopathic effects of CPE in cell culture medium and takes about three weeks (21). Therefore, PCR is a fast, sensitive, and highly specific method for determining the presence or absence of virus and genotype and serotype.

Table 3. Sequence similarity percentage of hexon gene between Iranian strains and reference strain

	1	2	3	4	5	6	7	8	9	10	11	12	13	14	15	16	17	18	19	20	
1	DQ323984.1	100.00																			
2	MG676334.1	100.00	100.00																		
3	MG676338.1	99.55	99.55	99.55																	
4	KY229179.1	100.00	100.00	100.00	99.55																
5	EF685644.1	100.00	100.00	100.00	99.55	100.00															
6	EF685524.1	97.37	97.37	97.37	97.25	97.37	97.37														
7	HM748590.1	100.00	100.00	100.00	99.55	100.00	100.00	97.37													
8	MK642677.1	96.90	96.90	96.90	96.90	96.90	96.90	96.24	96.90												
9	LC483160.1	97.02	97.02	97.02	97.03	97.02	97.02	96.37	97.02	98.50											
10	MK642679.1	97.89	97.89	97.89	97.89	97.89	97.89	96.75	97.89	97.02	98.50										
11	LC483158.1	100.00	100.00	100.00	99.55	100.00	100.00	97.37	100.00	97.02	97.02	97.89									
12	MK468900.1	100.00	100.00	100.00	99.55	100.00	100.00	97.37	100.00	98.49	97.02	97.89	100.00								
13	MK468900.1	97.14	97.14	97.14	97.14	97.14	97.14	96.63	97.14	98.49	98.49	98.61	97.14	97.14							
14	JX257176.1	97.14	97.14	97.14	97.14	97.14	97.14	96.63	97.14	98.38	98.49	98.61	97.14	97.14	99.89						
15	LN907532.1	97.02	97.02	97.02	97.02	97.02	97.02	96.50	97.02	98.49	98.38	98.50	97.02	97.02	100.00	99.89					
16	LN907534.1	97.14	97.14	97.14	97.14	97.14	97.14	96.63	97.14	98.49	98.49	98.61	97.14	97.14	100.00	100.00	99.89				
17	Iran_IBH	97.14	97.14	97.14	97.14	97.14	97.14	96.63	97.14	98.50	98.49	98.61	97.14	97.14	99.32	100.00	99.89	100.00			
18	MG953207.1	96.64	96.64	96.64	96.65	96.64	96.64	96.25	96.64	98.49	98.50	98.14	96.64	96.64	100.00	99.32	99.21	99.32	99.32		
19	KT037701.1	97.14	97.14	97.14	97.14	97.14	97.14	96.63	97.14	100.00	98.49	98.61	97.14	97.14	100.00	100.00	99.89	100.00	100.00	99.32	
20	KU647792.1	97.14	97.14	97.14	97.14	97.14	100.00	96.63	97.14	98.85	98.49	98.61	97.14	97.14	100.00	100.00	99.89	100.00	100.00	99.32	100.00

As mentioned earlier, IBH can lead to immunosuppression and predispose poultry to other diseases, including avian influenza and Newcastle disease (14). On the other hand, having IBH at a young age due to the weakening of the immune system has forced poultry clinicians to postpone and change the vaccination schedule of the herd, which in turn has increased the susceptibility of the herd to common diseases grown on farms. Weakening of the immune system due to certain viral diseases, stress, and adverse environmental conditions can increase the pathogenicity of adenoviral infections. Adenoviruses are one of the causes of immunosuppression in broilers, in addition to subclinical infections of bursal disease (22). Schonville et al. (2008) showed that in vitro adenovirus infection of four birds leads to depletion of B and T lymphocytes in lymphoid organs in pathogen-free chickens (SPF) (23). Some studies in Canada (2006) support the hypothesis that IBH in broilers is a primary disease without known immunosuppressive agents (24).

This study was performed on a 20,000-piece broiler flock in Kashan in 1397. PCR identified the IBH virus, and its histopathological lesions were also studied. In this study, phylogenetic analyses were performed based on hexon gene nucleotide sequences.

The strains studied in this study (Iran IBH), with strain KU647792.1 from Spain, LN907532.1 and LN907534.1 from Austria, JX257176.1 from Sweden, and the MG95 3207.1 from Hungary, are in the same group (Fig. 4). The Iranian strain is almost 100% similar to the mentioned strains (Table 3). Spanish strains belong to serotypes 8b and 11.

Conclusion

According to the phylogenetic analysis, the Iranian isolate in this research was similar to European countries' isolates. More epidemiological studies need to be done. The pathogenesis of the IBH virus should also be investigated.

Acknowledgment

The authors would like to thank the Ghalyanchi lab experts at the University of Tehran for their extensive technical supports.

Conflict of interest

No conflict of interest is declared.

Funding

This study was not financially supported by any individual, agency, or institution.

References

- Adair B, Fitzgerald SD. Group I adenovirus infections. In: Saif, YM; Fadly, AM; Glisson, JR; McDougald, LR; Nolan, LK and Swayne, DE (Eds.), *Diseases of poultry*. (12th Edn.), Ames, IA., USA, Iowa State University Press. 2008;PP:252-66.
- Helmboldt C, Frazier M. Avian hepatic inclusion bodies of unknown significance. *Avian Dis*. 1963;7:446-50.
- Erny K, Barr D, Fahey KJ. Molecular characterization of highly virulent fowl adenoviruses associated with outbreaks of inclusion body hepatitis. *Avian Pathol*. 1991;20:597-606.
- Hafez HM. Avian adenoviruses infections with special attention to inclusion body hepatitis/hydro-pericardium syndrome and egg drop syndrome. *Pak Vet J*. 2011;31:85-92.
- McFerran J, Adair B. Avian adenoviruses-a review. *Avian Pathol*. 1977;6:189-217.
- Grimes T, King D, Kleven S, Fletcher O. Involvement of a type-8 avian adenovirus in the etiology of inclusion body hepatitis. *Avian Dis*. 1977;21:26-38.
- Herdt Pd, Timmerman T, Defoort P, Lycke K, Jaspers R. Fowl adenovirus infections in Belgian broilers: a ten-year survey. 2013;82:125-32.
- Benson D, Karsch-Mizrachi I, Lipman D, Ostell J, Wheeler D. *GenBank Nucleic Acids Res*. 2008;33:D34-38.
- Steer PA, Kirkpatrick NC, O'Rourke D, Noormohammadi AH. Classification of fowl adenovirus serotypes by use of high-resolution melting-curve analysis of the hexon gene region. *J Clin Microbiol*. 2009;47:311-21.
- Lim T-H, Lee H-J, Lee D-H, Lee Y-N, Park J-K, Youn H-N. Identification and virulence characterization of fowl adenoviruses in Korea. *Avian Dis*. 2011;55:554-60.
- Hosseini H, Morshed R. Molecular identification of fowl adenovirus associated with inclusion body hepatitis in Iran. *Iranian J Virol*. 2012;6:7-12.
- Meulemans G, Boschmans M, Van den Berg T, Decaesstecker M. Polymerase chain reaction combined with restriction enzyme analysis for detection and differentiation of fowl adenoviruses. *Avian Pathol*. 2001;30:655-60.
- Rahimi M, Haghighi Z. Adenovirus-like inclusion body hepatitis in a flock of broiler chickens in Kermanshah province, Iran. *Vet Res Forum*. 2015;6:95-8.
- Khodakaram-Tafti A, Asasi K, Namazi F. Clinicopathological characteristics of acute inclusion body hepatitis outbreak in broiler chickens in Iran. *Bulg J Vet Med*. 2016;19:163-8.
- Mayahi M. Detection and identification of avian adenovirus in broiler chickens suspected of inclusion body hepatitis in Khuzestan, Iran during 2015-2016. *Iran J Vet Sci and Tech*. 2017;9:41-5.
- Nateghi E, Razmyar J, Bassami MR. Molecular characterization of avian adenoviruses in Iranian broiler flocks. *Iran J Vet Res*. 2014;15:164-7.
- Morshed R, Hosseini H, Ghalyanchi Langeroudi A, Bozorgmehri Fard MH, Charkhkar S. Fowl adenoviruses D and E cause inclusion body hepatitis outbreaks in broiler and broiler breeder pullet flocks. *Avian Dis*. 2017;61:205-10.
- Ghorbani M., Hatfinejad K., Shayegh J. Identification of IBH by PCR method in broiler chickens south of Isfahan province [in persian]. 11th Iranian Veterinary Students Congress. 1396.
- Zadravec M, Slavec B, Krapež U, Kaján GL, Račnik J, Juntos P, et al. Inclusion body hepatitis associated with fowl adenovirus type 8b in broiler flock in Slovenia-a case report. *Slov Vet Res*. 2011;48:107-113.
- Mettifogo E, Nuñez LF, Santander Parra SH, Astolfi-Ferreira CS, Ferreira AJ. Fowl adenovirus group I as a causal agent of inclusion body hepatitis/hydro-pericardium syndrome (IBH/HPS) outbreak in brazilian broiler flocks. *Pesq Vet Bras*. 2014;34:733-7.
- Cowen B, Lu H, Weinstock D, Castro A. Pathogenicity studies of fowl adenoviruses isolated in several regions of the world. *Proc International Symposium on Adenovirus and Reovirus Infection in Poultry, Rauischholzhausen, Germany*. 1996;79-88.
- Hoerr FJ. Pathogenesis of enteric diseases. *Poult Sci*. 1998;77:1150-5.
- Schonewille E, Singh A, Göbel TW, Gerner W, Saalmüller A, Hess M. Fowl adenovirus (FAdV) serotype 4 causes depletion of B and T cells in lymphoid organs in specific pathogen-free chickens following experimental infection. *Vet Immunol Immunop*. 2008; 121:130-9.
- Gomis S, Goodhope R, Ojkic D, Willson P. Inclusion body hepatitis as a primary disease in broilers in Saskatchewan, Canada. *Avian Dis*. 2006;50:550-5.