

Original Article

Fowl Adenoviruses E Cause Inclusion Body Hepatitis Outbreaks in Broiler Flocks: Detection and Phylogenetic Analysis

Leila Aghaiyan¹, Hossein Hosseini², Zahra ZiafatiKafi¹, Hamideh Najafi³, Mohammad Hossein Fallah Mehrabadi⁴, FatemehSadat Mousavi¹, Niusha Hajizamani¹, Arash Ghalyanchilangeroudi¹

1. Department of Microbiology and Immunology, Faculty of Veterinary Medicine, University of Tehran, Tehran, Iran .
2. Department of Clinical Sciences, Faculty of Veterinary Medicine, Islamic Azad University, Karaj Branch, Alborz, Iran.
3. Department of Pathobiology, School of Veterinary Medicine, Shiraz University, Shiraz, Iran.
4. Department of Poultry Diseases, Razi Vaccine, and Serum Research Institute, Agricultural Research, Education and Extension Organization (AREEO), Tehran, Iran.

Abstract

Background and Aims: Inclusion body hepatitis (IBH) associated with FAdV-I (fowl adenovirus) occurs worldwide in the poultry industry. It is an acute disease mainly affecting young chickens between 3 and 7 weeks of age. The objective of this study was to detect and establish the molecular sequences of the hexon gene from the avian adenovirus strains of group I (FAdV-I) from birds to characterize the serotype of the virus affecting commercial flocks in Iran.

Materials and Methods: Samples were obtained from 2-week old broiler flocks of Ross from Golestan province of Iran on March 2018. DNA was extracted by Sina Pure DNA extraction kit. The 590 bp region of the hexon gene was amplified using a pair of specific primers. The PCR products were sequenced in the forward and reversed direction.

Results: The nucleotide sequences of the hexon gene showed the existence of FAdV-8b from species E among broilers of Golestan province.

Conclusions: This is the first report of FADV in broiler farms in Golestan province, Iran. The FAdV sequences obtained in this work shared 100% homology to those previously found in Iran(2013), Italy, Hungary, China, and Peru. Molecular characterization of viruses circulating in different regions of the country is essentially needed to develop effective vaccines.

Keywords: Inclusion Body Hepatitis, Adenovirus, Iran, Detection.

Introduction

Adenoviruses (AdVs) are non enveloped double-stranded DNA viruses, which belong to the family Adenoviridae.

The family Adenoviridae is currently divided into five genera: Mastadenovirus, Aviadenovirus, Atadenovirus, Siadenovirus, and Ichtadenovirus. Avian adenovirus is composed by 3 groups (I–III) [1], and classified into 5 species (A–E) and 12 serotypes (*FAdV-1*, *FAdV-2*, *FAdV3*, *FAdV-4*, *FAdV-5*, *FAdV-6*, *FAdV-7*, *FAdV-8a*, *FAdV8b*, *FAdV-9*, *FAdV-10*, *FAdV-11*[2]. The viral capsid has 252 capsomeres, of which 240 are formed by the hexon protein and 12 by the penton protein, which forms the vertices from which fibers that have antigenic properties become detached [2]. FAdVs are

* **Corresponding author:** ArashGhalyanchilangeroudi
Department of Microbiology and Immunology, Faculty of Veterinary Medicine, University of Tehran, Azadi Ave, Tehran, Iran. PO.Cod:1419963111, Tel: 021-61117154, Email: arashghalyanchi@gmail.com, ghalyana@ut.ac.ir

transmitted vertically and horizontally via all excretions, but the highest titers are found in feces [3]. FAdVs have been isolated from healthy and diseased domestic fowl, and the most important diseases associated with FAdVs in the chicken are inclusion body hepatitis (IBH), hydropericardium hepatitis syndrome (HHS), and gizzard erosion [4, 5]. IBH is an acute disease mainly affecting young chickens between three to seven weeks of age [6] and is usually caused by FAdV-D and FAdV-E [7-10]. IBH was first described in the domestic chicken by Helmboldt and Frazier in 1963 [11]. It is characterized by acute hepatic necrosis and by the presence of intranuclear mauve-colored inclusion bodies in the hepatocytes [11]. McFerran et al. 1976 [12] later demonstrated that it was due to an infection induced by an adenovirus. Electron microscope studies have revealed the presence of adenovirus-like particles in cases of hepatitis associated with necrosis and intranuclear inclusion bodies in several avian species, including the kestrel [9], pigeon [13], goose [14], tawny frogmouth [8] merlin [15], cockatiel (*Nymphicus hollandicus*) [16] and in a peach-faced love-bird (*Agapornis roseicollis*) [17]. Polymerase chain reaction (PCR) using different primer sets, which can amplify the various regions of the hexon gene, followed by restriction enzyme digestion or nucleotide sequencing of the products, allows the differentiation of FAdVs [18].

Also, the combination of PCR and high resolution melting curve analysis has provided an accurate and rapid genotyping technique for the identification of FAdV serotypes [10].

In recent years, the number of IBH cases has increased in different provinces of Iran, particularly in broiler flocks [19]. The current study describes the molecular typing of FAdVs which is essentially needed to develop effective vaccines.

Methods

History. Samples were obtained from two IBH suspected broiler flocks of Ross from Golestan province of Iran on March 2018. Ten liver

specimens from two-week-old chickens were transmitted to the department of microbiology, University of Tehran, Tehran, Iran. The liver samples were homogenized. The supernatant obtained after centrifugation of the homogenized tissues was kept.

DNA Extraction. Viral DNA was extracted by Sina Pure DNA kit (Cinnaclon Co., Iran) according to the protocol of the manufacturer. The extracted DNA was collected in a sterile 1.5 ml microtube and stored at -18°C for the subsequent PCR process.

Polymerase Chain Reaction (PCR). The 590 bp region of the hexon gene was amplified using a pair of specific primers termed Hex L1-F and Hex L1-R [10]. PCR process was carried out in a 20 µl reaction volume containing 12.5 µl Taq DNA Polymerase Master Mix RED (Ampliqon III), 2x Ampliqon, one µl of each primer, 3 µl of ddH₂O and 2.5 µl extracted viral DNA.

Amplifications were performed in an Eppendorf master cycler gradient thermocycler (Eppendorf, Hamburg, Germany). The thermocycler was configured in the following conditions: 95°C for 3 minutes followed by 35 cycles of 95°C for 45 seconds, 53 °C for 45 seconds, 68°C for 60 seconds, and a final step at 68°C for 10 minutes. The reaction products were analyzed by electrophoresis on 1.5% agarose gels in TAE buffer, stained with GelRed™ (Biotium, USA) and visualized under UV light.

Phylogenetic analysis. The PCR products were sequenced in the forward and reverse direction. Bioneer Company performed sequencing reactions (Korea). Sanger dideoxy sequencing methods were used to obtain these sequences. The sequences derived were analyzed using the BLAST search program (<http://blast.ncbi.nlm.nih.gov/Blast.cgi>).

The nucleotide sequences of the hexon gene were compared with the FAdV sequences data available in the National Center for Biotechnology Information, and the phylogenetic relationship was established. The sequences were aligned using the ClustalW with MEGA7 software (The Biodesign Institute, Arizona, USA).

Fowl Adenoviruses E Cause Inclusion Body Hepatitis Outbreaks in Broiler Flocks...

Table 1. Sequence similarity matrix calculated by Mega7 among Iranian fowl adenoviruses and other selected FAdVs.

		1	2	3	4	5	6	7	8	9	10	11	12	13	14	15	16	17
1	5630(HM592279.1)																	
2	09-8330(FN869965.1)	100.00																
3	14406(KC750803.1)	100.00	100.00															
4	038(G765468.1)	100.00	100.00	100.00														
5	033(MG765465.1)	100.00	100.00	100.00	100.00													
6	032(MG765464.1)	100.00	100.00	100.00	100.00	100.00												
7	023(MG765463.1)	100.00	100.00	100.00	100.00	100.00	100.00											
8	022(MG765462.1)	100.00	100.00	100.00	100.00	100.00	100.00	100.00										
9	021(MG765461.1)	100.00	100.00	100.00	100.00	100.00	100.00	100.00	100.00									
10	SD16(KY426984.1)	100.00	100.00	100.00	100.00	100.00	100.00	100.00	100.00	100.00								
11	140614(KU981150.1)	100.00	100.00	100.00	100.00	100.00	100.00	100.00	100.00	100.00	100.00							
12	BIO6(KX755573.1)	100.00	100.00	100.00	100.00	100.00	100.00	100.00	100.00	100.00	100.00	100.00						
13	FV211(KX258422.1)	100.00	100.00	100.00	100.00	100.00	100.00	100.00	100.00	100.00	100.00	100.00	100.00					
14	AGZ1	96.94	96.94	96.94	96.94	96.94	96.94	96.94	96.94	96.94	96.94	96.94	96.94	96.94				
15	AGZ2	100.00	100.00	100.00	100.00	100.00	100.00	100.00	100.00	100.00	100.00	100.00	100.00	100.00	96.94			
16	H1621.2(KY019225.1)	67.05	67.05	67.05	67.05	67.05	67.05	67.05	67.05	67.05	67.05	67.05	67.05	67.05	63.99	67.05		
17	H651.3(KY019206.1)	100.00	100.00	100.00	100.00	100.00	100.00	100.00	100.00	100.00	100.00	100.00	100.00	100.00	96.94	100.00	67.05	

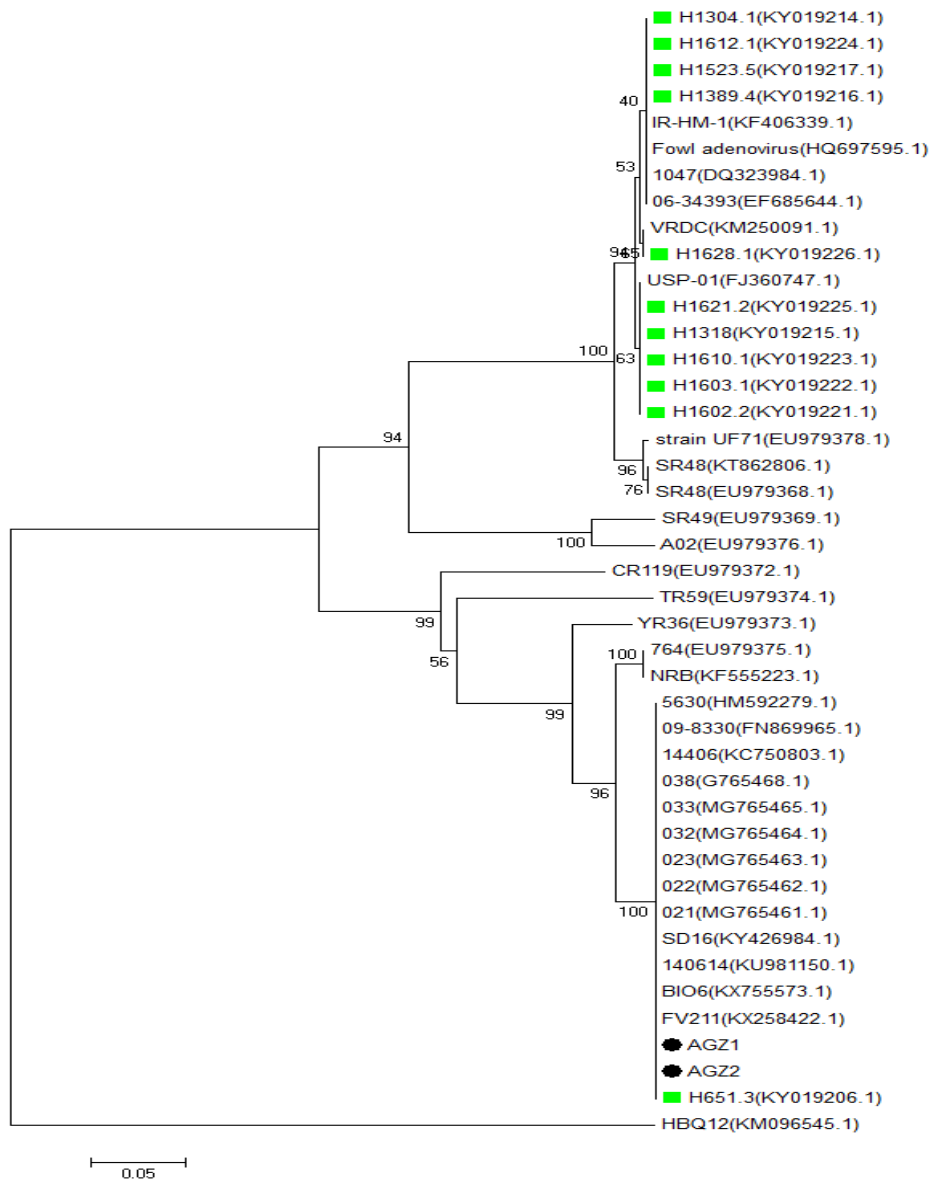


Fig. 1. Hexon gene-based neighbor-joining tree constructed by MEGA (7.0) package with 1000 replicates. Viruses detected in this study are marked with black dots. Previously detected fowl adenoviruses in Iran are bolded with green squares.

A distance-based neighbor-joining tree was constructed by using the Tamura-Nei model [20]. 1000 bootstrap replicates assessed the robustness of the phylo-genetic tree.

Results

PCR and sequence analysis typed one FADV from broilers. According to the results of phylogenetic analysis, based on the partial hexon gene sequence, the viruses were located in FAdV-E serotype 8b. One virus showed the 100% sequence homology to the FADV-8b isolates of Iran, China, Peru, Italy, Austria, and Hungary while the rate of similarity of the other virus with 8b isolates was 96.94% (Table 1 and Figure 1).

Discussion

Avian adenoviruses are distributed worldwide, causing different kinds of disease, including inclusion body hepatitis, hepatitis-hydropericardium syndrome (HHS), and respiratory and enteric conditions.

David De la Torre. *et al.* [21] analyzed the hexon gene of group I FAdVs isolated from birds with the hepatitis-hydropericardium syndrome (HHS), malabsorption syndrome, and running-stunting syndrome. They proved the circulation of FAdV-8a, FAdV-8b, and FAdV-11 serotypes in Brazilian poultry flocks. Morshed *et al.* [22] isolated adenoviruses from broilers and broiler breeder pullets in Iran. Phylogenetic analyses based on partial hexon gene showed the presence of two species D and E. [3]. Identification of FAdV serotypes is important in epidemiologic studies of disease outbreaks, the development of preventative measures, and the adoption of vaccination strategies. Nucleotide sequence diversity analysis is a reliable molecular epidemiology method for characterization of FAdV viruses. This study is a report on the distribution of FAdVs in Golestan province of Iran besides molecular characterization. It appears that IBH has been recently increasing in meat-type chickens in Iran that can result in large economic losses to the poultry industry.

Phylogenetic analysis based on the nucleotide sequence of the variable region L1 of the hexon gene classified the nucleotide sequences into three distinct groups and confirmed the presence of the serotypes 8a and 8b of the E species in Iranian poultry flocks.

These results emphasize the worldwide distribution of FAdV-I since serotype 8a aligned with a reference strain from Japan, serotype 8b with a UK reference strain, and serotype 11 with a reference strain from Belgium. Other studies will be necessary to associate the pathogenicity of these serotypes with the clinical changes described.

It is necessary to provide more epidemiological data to establish the prevalence of these viruses and justify the development of vaccine programs in breeders, broiler and laying hens to prevent vertical and horizontal virus infections and prevent the spread of this virus [23].

Conclusions

The results of the phylogenetic analysis showed that the partial hexon gene sequence of the isolate was similar to FAdV-E serotype 8b.

Acknowledgments

The authors gratefully acknowledge Mofeed Company for providing the grant for this project and Ghalyanchilab experts, especially Dr. Modiri for extensive technical supports.

References

1. Hess M. Detection and differentiation of avian adenoviruses: a review. *Avian Pathol.* 2000;29 (3): 195-206.
2. Suarez D. Avian encephalomyelitis. In (eds: Swayne DE, Glisson Jr, McDougald Lr, Nolan LK, Suarez DL, Nair V) *Diseases of Poultry* 13th edn, Ames. 2013, Wiley-Blackwell.
3. Gomis S, *et al.* Inclusion body hepatitis as a primary disease in broilers in Saskatchewan, Canada. *Avian Dis.* 2006;50(4):550-555.
4. Marek A, Schulz E, Hess C, Hess M. Comparison of the fibers of Fowl adenovirus A serotype 1 isolates from chickens with gizzard erosions in Europe and apathogenic reference strains. *J Vet Diagn Invest.* 2010;22(6):937-941.

5. Niu, Y.-j., Sun W, Zhang G-H, Qu Y-J, PWang P-F, Sun H-L, et al., Hydropericardium syndrome outbreak caused by fowl adenovirus serotype 4 in China in 2015. *J Gen Virol.* 2016;97(10):2684-2690.
6. Steer PA, Sandy JR, O'Rourke D, Scott PC, Browning GF, Noomohammadi AH. Chronological analysis of gross and histological lesions induced by field strains of fowl adenovirus serotypes 1, 8b and 11 in one-day-old chickens. *Avian Pathol.* 2015;44(2): 106-113.
7. Ramis A, Marlasca MJ, Majo N, Ferrer L. Inclusion body hepatitis (IBH) in a group of eclectus parrots (*Eclectus roratus*). *Avian Pathol.* 1992;21(1):165-169.
8. Reece R, Pass D, Butler R. Inclusion body hepatitis in a tawny frogmouth (*Podargus strigoides*: Caprimulgiformes). *Aust Vet J.* 1985;62(12):426-426.
9. Sileo L, Franson JC, Graham DL, Domermuth CH, Rattner BA, Pattee OH. Hemorrhagic enteritis in captive American kestrels (*Falco sparverius*). *J Wildl Dis.* 1983;19(3):244-247.
10. Steer PA, Kirkpatrick NC, O'Rourke D, Noor-mohammadi AN. Classification of fowl adenovirus serotypes by use of high-resolution melting-curve analysis of the hexon gene region. *J Clin Microbiol.* 2009; 47(2):311-321.
11. Helmboldt, C. and M. Frazier, Avian hepatic inclusion bodies of unknown significance. *Avian Dis.* 1963;7(4):446-450.
12. McFerran J, McCracken RM, Connor TJ, Evans RT. Isolation of viruses from clinical outbreaks of inclusion body hepatitis. *Avian Pathol.* 1976;5(4): 315-324.
13. Coussement W, et al. Pathologie van adenovirus-infekties bij duiven. *Vlaams Diergeneeskd Tijdschr.* 1984;53:277-283.
14. Goryo M, Ueda Y, Umemura T, Haruna A, Itakura C. Inclusion body hepatitis due to adenovirus in pigeons. *Avian Pathol.* 1988;17(2):391-401.
15. Schelling S, Garlick D, Alroy J. Adenoviral hepatitis in a merlin (*Falco columbarius*). *Vet Pathol.* 1989;26(6): 529-530.
16. Scott, P., R. Condron, and R. Reece, Inclusion body hepatitis associated with adenovirus-like particles in a cockatiel (*Psittaciformes*; *Nymphicus hollandicus*). *Aust Vet J.* 1986; 63(10):337-338.
17. Pass D. Inclusion bodies and hepatopathies in psittacines. *Avian Pathol.* 1987;16(4):581-597.
18. Hosseini H, Morshed R. Molecular identification of fowl adenovirus associated with inclusion body hepatitis in Iran. *Iran J Virol.* 2012;6(4):7-12.
19. Nateghi E, Razmyar J, Bassami MR. Molecular characterization of avian adenoviruses in Iranian broiler flocks. *Iran J Vet Res.* 2014;15(2):164-167.
20. Tamura K, Peterson D, Peterson N, Stecher G, Nei M, Kumar S. MEGA5: molecular evolutionary genetics analysis using maximum likelihood, evolutionary distance, and maximum parsimony methods. *Mol Biol Evol.* 2011;28(10): 2731-2739.
21. Chomczynski P. A reagent for the single-step simultaneous isolation of RNA, DNA and proteins from cell and tissue samples. *Biotechniques.* 1993; 15(3):536-7.
22. Morshed, R, Hosseini H, Ghalyanchi Lange-roudi A, Bozorgmehri Fard MH, Charkhkar S. Fowl adenoviruses D and E cause inclusion body hepatitis outbreaks in broiler and broiler breeder pullet flocks. *Avian Dis.* 2017;61(2):205-210.
23. Grgic H, Philippe C, Ojkic D, Nagy E. Study of vertical transmission of fowl adenoviruses. *Can J Vet Res.* 2006;70(3):230.