

## Case Report

# COVID-19 Case Report from an Asymptomatic Patient

Mehrbod P<sup>1</sup>, Fotouhi F<sup>1</sup>, Farahmand B<sup>1\*</sup>

1. Influenza and Respiratory Viruses Department, Pasteur Institute of Iran, Tehran, Iran.

### Abstract

**Background and Aims:** The novel coronavirus (2019-nCoV), one of the most important infectious diseases of the current decade causes a severe respiratory global pandemic. This case report study aimed to report the symptoms and lab identification of a patient confirmed with COVID-19 infection with no respiratory symptoms compared to few other cases.

**Keywords:** COVID-19, Coronavirus, Homeopathy

### Introduction

COVID-19 one of the most important infectious diseases causes a severe respiratory global pandemic that was unknown in the human before. In 2003 and 2013, two viruses of this family (SARS and MERS, respectively) led to high mortality and economic losses in a short period and limited areas [1, 2].

This new disease was first reported on December 8, 2019 in Wuhan City, Hubei Province, China and spread all over the world very fast [3]. It can cause respiratory, enteric, hepatic, and neurologic diseases [4] with various symptoms.

### Case Presentation

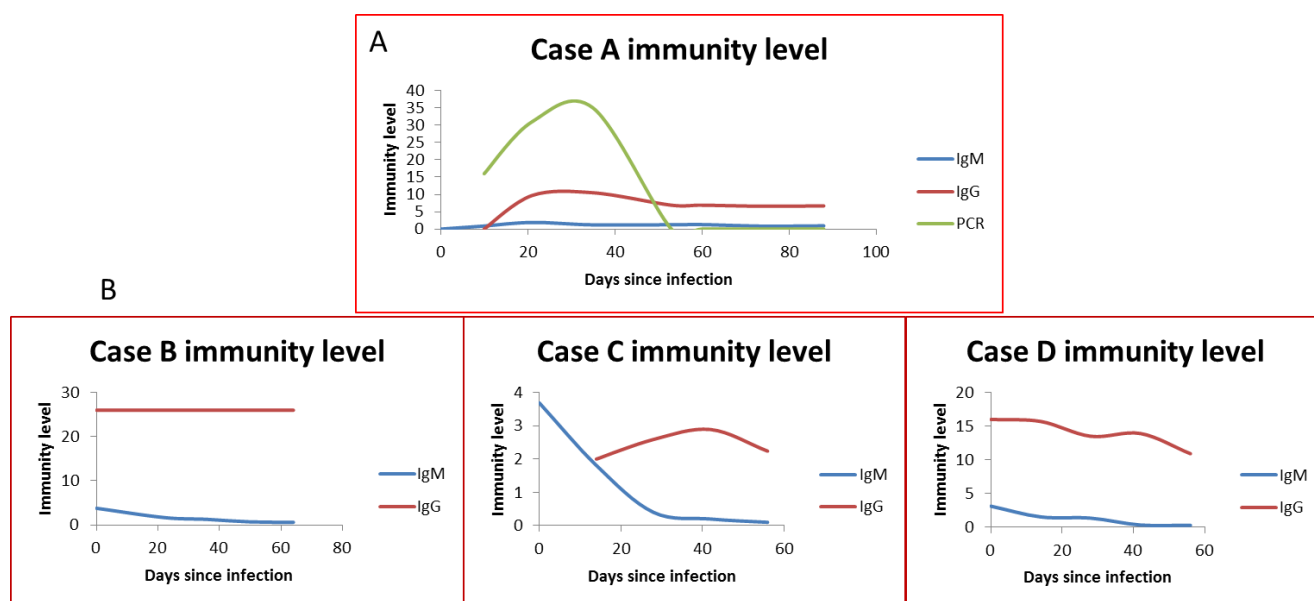
A 44-year-old woman with the history of malignant breast cancer treatment in 5 years ago, who lives in Tehran, Iran, experienced the signs of a mild cold on March 12, 2020. She

had no serious problem and no other symptoms. The symptoms gradually increased after 1 week which included mild sore throat, headache, sinus congestion, fatigue, muscle ache, joint ache, insomnia, periodic fever (38.5°C) and chills for 2 weeks. There was no respiratory symptom and there was not suspected to be COVID-19 infection.

Therefore, she did not refer to medical center and took only home remedies and herbal decoctions in this period. After 2 weeks, the symptoms continued although no respiratory symptom occurred yet. She referred to Pasteur Institute of Iran for coronavirus Real-time PCR test. The test was positive for the throat swab sample.

Then, she started drug medication under physician control. The prescription included Azithromycin 250 mg every 24 hr, hydroxy-chloroquine 200 mg every 12 hr and diphenhydramine syrup every 6 hr. Fruit juice and multivitamin supplements were also taken in parallel. Meanwhile, she lost senses of smell and taste.

<sup>1</sup>**Corresponding author:** Behrokh Farahmand, Influenza and Respiratory Viruses Department, Pasteur Institute of Iran, Tehran, Iran. Tel: (+98) 21-64112183, Email: farahmand.b2@gmail.com.



**Fig. 1.** (A) IgM and IgG antibodies levels and Ct values in periodical tests for the case A. (B) Three other cases IgM and IgG antibodies levels.

Followed by that, she got better gradually, symptoms started to fade and she underwent periodical Real-time PCR and antibody tests for almost 3 months. Her symptoms continued to 40 days and her recovery took long time.

The results are shown in Figure 1A. The course of results improvement was desired and favorable. As shown in the figure, the PCR test result was acceptable. The IgM dropped and IgG remained stable although not very high (6.5). Three other cases were also evaluated regarding their immunity level to compare the condition (Figure 1B).

Two of these cases were outpatient with high (26) and low (2.25) IgG levels for 8 weeks follow-up and one case was inpatient, obese with moderate (10.9) IgG level. None of them had auto immune and or immunity problem. All of them were treated and recovered normally.

**Medical history.** This patient had a history of severe seasonal, food and drug allergies since childhood. She was diagnosed with malignant breast cancer 5 years ago. After lumpectomy, she underwent 10 sessions of chemotherapy and 35 sessions of radiotherapy.

She was fully recovered of her cancer but later on suffered from digestive tract problem, hemorrhoid and Hashimoto's thyroiditis with high level of anti-TPO as side effects of her

cancer treatment. During these years she had periodical checkups and took chemical drugs which were not effective for treatment. Then, she started taking homeopathy medication (K.P 6x; potassium phosphate and NM 6x; sodium chloride) under physician control for these issues which was very effective and all the symptoms subsided so that her need for synthetic and chemical drugs was eliminated and her health condition was in optimum level. After COVID-19 infection and taking chemical drugs, all the symptoms of digestive problem and hemorrhoid raised again. Thus, she switched back to homeopathy remedy and her health condition improved. Her treatment was based on K.P 6x.

Patients with autoimmune disease and chronic illnesses are considered to be at risk and more susceptible to infectious diseases especially this new viral infection, COVID-19, which has several unknown aspects. On one hand, more severe symptoms may occur in these patients, on the other hand, not any kind of medication are safe to prescribe for them.

This case had no contact with any case disease except taking public transport. Although she used to wear mask and respected all the hygiene proceedings, she might have taken it from infected air droplets accidentally.

However, her immune system was booted by taking homeopathy medication and it may have been helpful to combat this disease much easier as no serious symptoms raised. Also, her IgG antibody level did not drop after almost 3 weeks.

This report suggests that even after taking good care there might be chances of getting this infection. And public transports which do not care much about disinfecting the surfaces and move countless numbers of passengers daily are surely critical and main sources of infectious diseases transmission.

Another important and thought-provoking aspect is the effect of traditional medicine especially homeopathy remedies as alternative or supplemental medication which should be considered as a suitable and safe medication for susceptible patients as it might be helpful in keeping the immunity level boosted.

## Acknowledgments

The authors thank colleagues in Influenza and Respiratory Viruses Department, Pasteur Institute of Iran for their unsparing collaboration.

## References

1. Poon LLM, Peiris M. Emergence of a novel human coronavirus threatening human health. *Nat Med.* 2020; 26(3):317-9.
2. Peiris J, Lai S, Poon L, Guan Y, Yam L, Lim W, et al. Coronavirus as a possible cause of severe acute respiratory syndrome. *Lancet.* 2003;361(9366):1319-25.
3. Zhu N, Zhang D, Wang W, Li X, Yang B, Song J, et al. A Novel coronavirus from patients with pneumonia in China, 2019. *N Engl J Med.* 2020;382(8):727-33.
4. Su S, Wong G, Shi W, Liu J, Lai AC, Zhou J, et al. Epidemiology, genetic recombination, and pathogenesis of coronaviruses. *Trends Microbiol.* 2016;24(6):490-502.