

## Original Article

# Genotyping of Fowl Adenoviruses Detected from Inclusion Body Hepatitis in Iran, 2020

Moarefian F<sup>1</sup>, Mortazavi P<sup>2</sup>, Hosseini H<sup>3</sup>, Parvandar Asadollahi K<sup>4\*</sup>

1. Faculty of Veterinary Medicine, Science and Research Branch, Islamic Azad University, Tehran, Iran.
2. Department of Pathology, Faculty of Veterinary Medicine, Science and Research Branch, Islamic Azad University, Tehran, Iran.
3. Department of Clinical Sciences, College of Veterinary Medicine, Karaj Branch, Islamic Azad University, Karaj, Iran.
4. Department of Clinical Sciences, Faculty of Veterinary Medicine, Science and Research Branch, Islamic Azad University, Tehran, Iran.

## Abstract

**Background and Aims:** Inclusion body hepatitis (IBH) is one of the most critical diseases in many countries with intensive poultry industries. In Iran, the etiological agent of IBH (fowl adenovirus) has been confirmed. This study aimed to determine the molecular detection and identification of fowl adenovirus involving IBH in chicken flocks during the year of 2020 in Iran.

**Materials and Methods:** For this purpose 150 liver tissue samples from 15 broilers flocks suspected in IBH infection were collected from Mazandaran province and were subjected to PCR analysis and histopathological examination. Polymerase chain reaction (PCR) and sequence analysis of the L1 hexon gene were utilized to detect and determine Fowl adenovirus (FAdV) genotypes in broiler farms. Histopathological sections were prepared and examined.

**Results:** FAdV infection was confirmed by PCR in 14 out of 15 broiler flocks. Based on sequencing analysis of the hexon gene, they were genetically related to FAdV-11, a member of the fowl adenovirus D species. Homology among the isolates, Iranian isolates, and other counties was 94.44% - 97.11%. Histological examination revealed necrotizing hepatitis with basophilic and eosinophilic intranuclear inclusion bodies in the hepatocytes.

**Conclusion:** The results confirm previous reports about high prevalence of FAdV infection in broiler flocks and show continuous circulation of genotype 11 in Iranian broiler flocks.

**Keywords:** Fowl adenovirus, FAdV, Inclusion Body Hepatitis, Broiler, Iran, Hexon, Phylogenetic Analysis

## Introduction

Inclusion body hepatitis (IBH) was first described in 1963 in the USA. The disease has been reported in many other countries in the world. In recent years, the reemergence of IBH has increased the importance of adenoviruses infection in the poultry industries. Fowl adenoviruses (FAdVs) of the genus *Aviadenovirus* are the cause of hepatitis in birds even though other agents may also be involved (1). FAdVs from the *Adenoviridae* family, *Avi-*

*adenovirus* genus, are non-enveloped double-stranded DNA viruses that cause various clinical manifestations and are a growing concern of poultry farmers worldwide (2). FAdVs are transmitted vertically and horizontally, but the highest titres are found in faeces (3).

At first, fowl adenoviruses considered a secondary disease and perceived as opportunistic pathogens causing IBH in concurrent infection by immunosuppressive agents such as infectious bursal disease virus (IBDV) and chicken infectious anemia virus (CIAV), However, later, studies showed that the primary role FAdV in the etiology of the IBH (4, 5). Twelve types, named FAdV-1 to 8a, and FAdV-8b to 11, are classified into five

\* Corresponding author:

Kaveh Parvandar Asadollahi,

Email: kaveh\_parvandar@yahoo.com.

different species (A-E) based on restriction enzyme digest pattern and serum cross-neutralization test (6).

FAdV-4 pathogenic strains are the hepatitis-hydropericardium syndrome (HHS) causative agent, resulting in high mortality of 30–80%. gizzard erosion ulceration (GEU) is induced by FAdV-1 and FAdV-8 strains (3). Many different serotypes have been associated with natural outbreaks of IBH.

In particular, those belonging to the species D and E can cause severe liver damage, leading to IBH. The diagnosis of FAdV infections was conventionally performed based on serological assays. However, many laboratories were unable to run such serologic tests because of inaccessibility to a full panel of reference strains and antisera. Molecular methods such as PCR are suitable alternatives since they enable comparing the results with available gene sequences. The gene coding the major capsid protein, the hexon, and viral DNA polymerase targets PCR assays detecting FAdVs among which, the variable loop region of the hexon gene is usually used for FAdV typing (7). Recently, a high mortality rate in the first three weeks of life has been reported in some of the Iranian flocks (1,8). This study aimed to determine the molecular detection and identification of an Adenovirus involved in the field cases of IBH in Iran.

## Methods

**Case history:** In 2020, 150 liver tissue samples from 15 broilers flocks, 10 liver samples from each flock, suspected in IBH cases were collected from Mazandaran provinces and were subjected for PCR analysis and histopathological examination.

**Histopathology:** For histopathological examination, livers from the suspected carcasses and PCR positive flocks were fixed in 10% buffered formalin, embedded in paraffin, sectioned at 4 µm, stained with hematoxylin and eosin, and examined by light microscopy (1).

**DNA Extraction:** Liver samples were homogenized, and after centrifuging, the supernatant was isolated. DNA was extracted through Sinaclon DNA extraction kit (Sinaclon, Iran).

**FAdV detection by PCR:** A previously designated PCR was used to amplify a 590-bp region of the hexon gene that corresponded to nucleotides 301–323 and 868–890 of the hexon gene, respectively and included the sequence encoding the L1 loop of the hexon gene. The primer sequences were as follows: Hex L1-s 5' ATGGGAGCSACCTAYTTTCGACAT-3' and reverse primer: Hex L1-as 5' -AAATTGTCCCKRAANCCGATGTA-3'.

PCR was performed at a final volume of 25 µl reaction containing 1.25 mM deoxynucleoside triphosphate, 25 mM MgCl<sub>2</sub>, 2 µl of each primer at 25 µM, 5 µl of 5x PCR buffer, 1.25 U of DNA polymerase (Sinaclon, Iran) and 2 µl of extracted DNA. PCR thermal condition was a denaturation step of 94 °C for 2 min, followed by 40 cycles of 94°C for 20 sec, 56 °C for 20 sec, and 72 °C for 30 sec (4,9).

**Sequencing, bioinformatic and Phylogenetic analysis:** Five positive PCR products were sent for sequencing. Sequence trace files were analyzed individually using Chromas 2.6.5 software. A minimum of 590 bp of high-quality sequence (determined by the size of the fluorescence signal and clarity of the peak) is expected per trace file: nucleotide and amino acid sequences data analyzed by CLC viewer 8.0. The obtained sequences were submitted to GenBank. Hexon gene sequences of different genogroup isolates of *IBH* retrieved from GenBank.

Multiple sequence alignments were generated using ClustalW; the alignments were subsequently used to construct distance matrices using the Kimura 2- parameter model implemented in the MEGA software version.

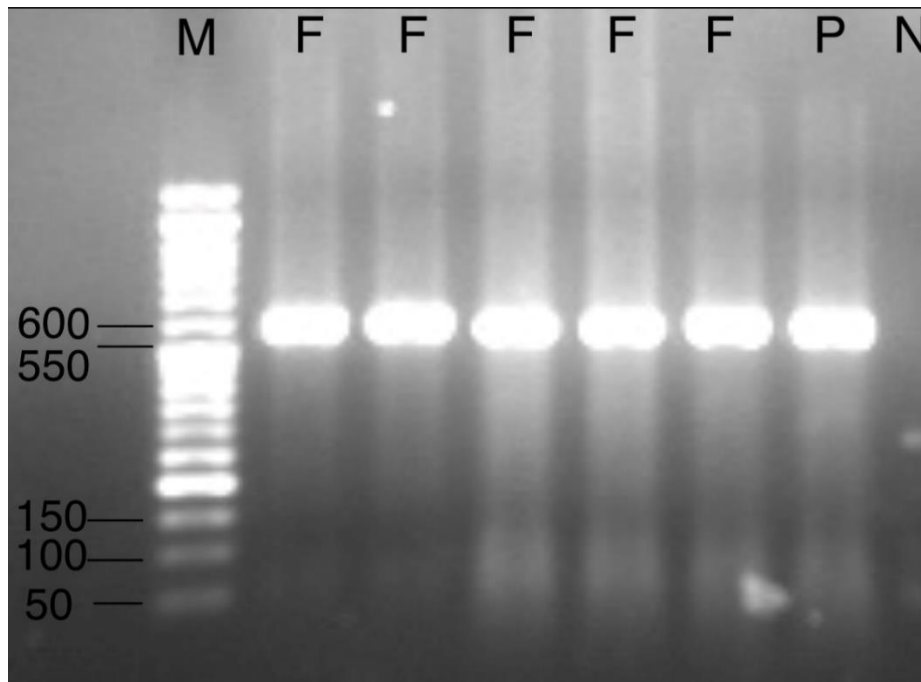
Neighbor-joining trees were plotted with Mega with a 1,000-fold bootstrap approach (10).

## Results

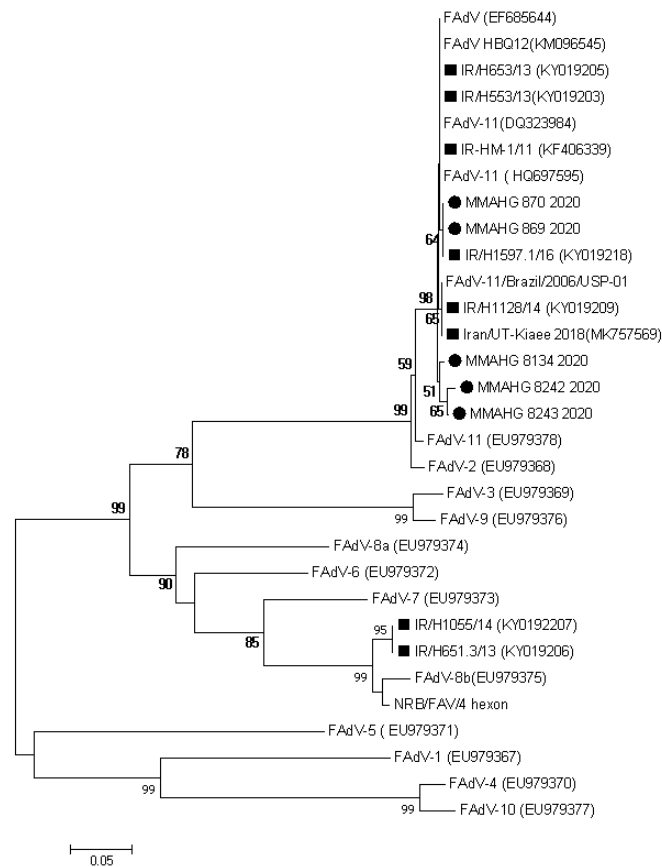
The presence of FAdV was confirmed by PCR amplification of a 590bp fragment from 14 affected broiler flocks (Figure 1).

All FAdVs detected in this work were clustered to species D and located with previously FAdVs reported from Iran in one cluster (figure 2).

## Genotyping of Fowl Adenoviruses detected from Inclusion Body Hepatitis



**Fig. 1.** PCR analysis. The 590 bp specific fragment from Hex L1-s /Hex L1-as primers: Lane M: 50 bp DNA ladder molecular weight marker (biotechrabbit 50 bp DNA Ladder, ready to use) Lane P: positive control (Isolate IR/H1603.1/16 (KY019222)). Lane N: negative control (Sterile distilled water). Lanes F: Fowl adenovirus positive samples.



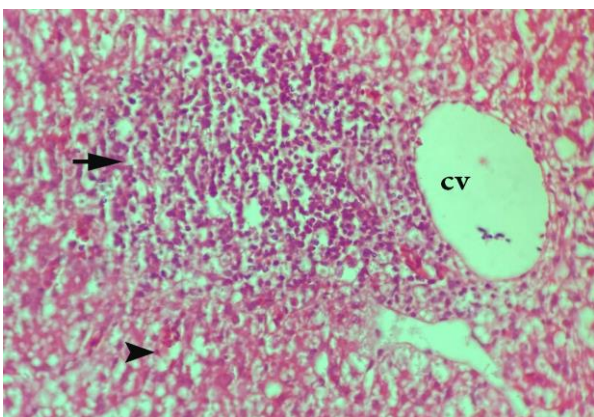
**Fig. 2.** Phylogenetic tree of a partial region (Gen Bank accession number Z67970, nt 301 to 890) of the Hexon gene by MEGA7 software (Neighbor-joining, Kimura 2-parameter, 1000 bootstraps). Fowl adenoviruses detected in this study are black circle.

		1	2	3	4	5	6	7	8	9
1	MMAHG/870/2020	#####								
2	MMAHG/8134/2020	98.98	####							
3	MMAHG/869/2020	100	99	#####						
4	MMAHG/8242/2020	97.92	99	97.92	####					
5	MMAHG/8243/2020	98.63	98.3	98.63	99.3	####				
6	FAdV-11 (EU979378)	97.23	96.9	97.23	96.5	97.2	####			
7	IR/H653/13(KY019205)	99.66	99.3	99.66	98.3	99	97.6	####		
8	Iran/UT-Kiaee/2018(MK757569)	99.32	99	99.32	97.9	98.6	97.2	99.7	####	
9	IR/H1597.1/16 (KY019218)	100	99	100	97.9	98.6	97.2	99.7	99.3	####

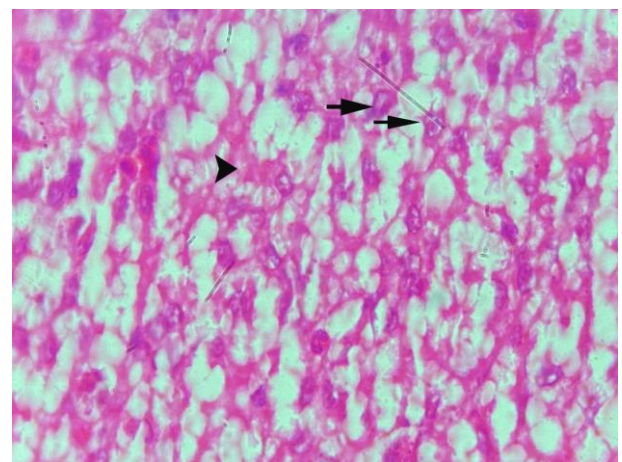
Recent FAdVs can be considered as genotype 11 and the homology among these isolates and previous Iranian FAdVs is 97.9%-100% (Table 1).

The homology between five recent FAdVs is 97.92%-100%. The sequence analysis of different Iranian FAdVs reveals that the circulating FAdVs in 2020 are close similar to those that reported in 2011 and 2013.

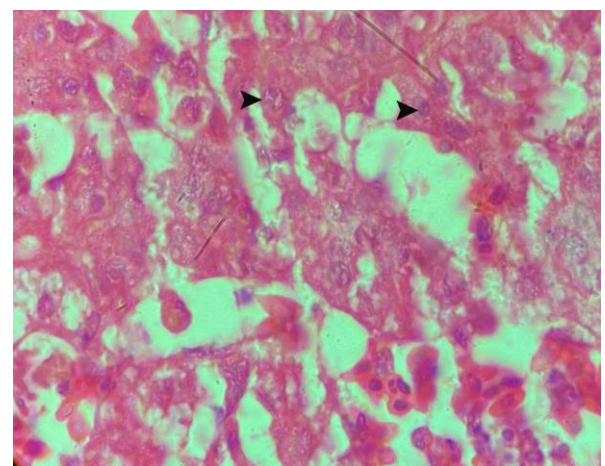
As the only genotype 11 was detected in this study, this genotype could be considered as dominant FAdVs that causing IBH in Iranian broiler flocks. The histopathological examination of livers revealed focal to diffuse necrosis of hepatocytes with the infiltration of mononuclear inflammatory cells and the presence of basophilic and eosinophilic intranuclear inclusion bodies in the necrotic hepatocytes (figure 3, 4, 5).



**Fig. 3.** A hematoxylin and eosin stained section of liver showing necrotic hepatocytes (tip of the arrow) infiltrated by mononuclear inflammatory cells (arrow) around central vein. 400 x magnification.



**Fig. 4.** A hematoxylin and eosin stained section of liver showing focal hepatocytes necrosis and eosinophilic intranuclear inclusion bodies (arrow), 1000 x magnification.



**Fig. 5.** A hematoxylin and eosin stained section of liver showing basophilic intranuclear inclusion bodies in hepatocytes (arrow), 1000 x magnification.

## Discussion

The first clinical cases of FAdVs have appeared in Pakistan, and consequently, the disease was reported from the USA (1995).

Germany (2013), Canada (2012), India (2014), China (2015), Korea (2012), Japan (2014), Mexico (2016), and Poland (2016) (11). In Iran, Hosseini *et al.*, in 2011, detected FAdVs from male broiler breeder farms from two regions in Iran. Partial hexon gene analysis clustered the viruses into D species (1).

Subsequently, an adenovirus-like inclusion body hepatitis was reported in 2012. The diagnosis was based on macroscopic, microscopic lesions, and high mortality of 2 day-old broilers (12). Morshed *et al.* isolated FAdVs from broiler and broiler breeder pullets with inclusion body hepatitis. Partial hexon gene analysis revealed the presence of species D and E among farms. They collected the samples from different provinces of Iran during 2013 and 2016. A FAdV isolated from Golestan province belonged to species D, serotype 11 (8). Another study was performed among broilers showing liver lesions and respiratory syndrome in northeast Iran.

Sequence analysis of the L1 region of the hexon gene proved the existence of FAdVs from serotypes 2, 8b, and 11 (4).

In the histopathology study of liver lesions, focal to diffuse necrosis of hepatocytes with the infiltration of mononuclear inflammatory cells were seen.

Also the presence of basophilic and eosinophilic intranuclear inclusion bodies in hepatocytes were observed. The main histopathological findings of this study is consistent with Khodakaram-Tafti *et al* and Ramis *et al* studies. (13 , 14). However, in the current study eosinophilic intranuclear inclusion bodies were found which this finding was not described by the above mentioned studies.

Ghafari *et al.* molecularly detected FAdVs in broilers of the southwest of Iran. Analysis of the hexon gene revealed that the FAdVs belonged to serotype 11 (15).

Recently, Hosseini *et al.* did full genome sequencing of an Iranian FAdV-11. According to the complete genome sequence analysis,

UT-Kiaee had high homology with Chinese and Canadian FAdV. The partial sequence of the hexon gene revealed that UT-Kiaee shared 100% identity with previous Iranian FAdVs (16). In Morocco Abghour *et al.* isolated and identified FAdVs in some poultry farms during 2015. In this study phylogenetic analysis of the hexon gene revealed that FAdVs isolated from different affected poultry belonged to FAdV 11 serotype of the D genotype group. This study same as current study shows the present of serotype 11 in other countries (17). In Pakistan Wajid *et al.* characterized FAdVs isolates from broiler and layer flocks during 2014 and 2015. This study revealed the presence of two distinct groups of FAdV-4 and FAdV-11 in chickens affected with hydropericardium syndrome and inclusion body hepatitis, this was the first report of FAdV-11 strains identified in poultry production facilities in Pakistan and shows spreading of this serotype in broiler and layer flocks in the region (18).

Based on the results of this study 14 of 15 flocks (93.3%) have been found FAdV positive. A very high percentage of positive flocks in this study can be associated with clinical symptoms and especially clear autopsy signs of the disease. The pattern of mortality in the age range of 2-3 weeks, as well as hepatitis with petechiae in the liver, is very helpful in the tentative diagnosis of this disease. Meanwhile, IBH cases have been prevalent in broiler flocks in recent years and practitioners are aware of total aspects of disease.

Five positive samples selected randomly and have been sequenced to find hexon gene sequences. The analysis of sequences hexon gene revealed that FAdVs belong to D species and genotype 11. The results confirm previous reports (1, 8) and show continuous circulation of genotype 11 in Iranian broiler flocks.

## Conclusion

In conclusion, this study provided updated data about the molecular characterization of FAdVs in Iran. The D species has been identified as causative agent of IBH for more than a decade in absent of vaccine in Iran may support the idea that the only way to control of this disease

is prophylactic vaccination of broiler-breeder flocks and implementation of a strong biosecurity programme to prevent contamination of the environment and birds on broiler farms.

### Acknowledgment

We would like to thank PCR lab experts and Dr. Ghalyanchi for their technical supports.

### Conflict of interest

No conflict of interest is declared.

### Funding

None

### References

- Hosseini H, Morshed R. Molecular identification of fowl adenovirus associated with inclusion body hepatitis in Iran. *Iran J Virol.* 2012;6(4):7-12.
- Kaján GL, Affranio I, Tóthné Bistyák A, Kecskeméti S, Benkő M. An emerging new fowl adenovirus genotype. *Heliyon.* 2019;5(5):e01732.
- Chen L, Yin L, Zhou Q, Peng P, Du Y, Liu L, et al. Epidemiological investigation of fowl adenovirus infections in poultry in China during 2015–2018. *BMC Vet Res.* 2019;15(1):271.
- Nateghi E, Razmyar J, Bassami MR. Molecular characterization of avian adenoviruses in Iranian broiler flocks. *Iran J Vet Res.* 2014;15(2):164-167.
- Gomis S, Goodhope AR, Willson P. Inclusion body hepatitis as a primary disease in broilers in Saskatchewan. *Can Avian Dis.* 2006;50:550-555.
- Zadavec M, Brigita S, Krapez U, Kajan GL, Racnik J, Polona J, et al. Inclusion body hepatitis (IBH) outbreak associated with fowl adenovirus type 8b in broilers. *Acta Vet (Beogr).* 2013;63(1):101-110.
- Kaján GL, Kecskeméti S, Harrach B, Benko M. Molecular typing of fowl adenoviruses, isolated in Hungary recently, reveals high diversity. *Vet Microbiol.* 2013;167(3-4):357-363.
- Morshed R, Hosseini H, Ghalyanchi Langeroudi A, Bozorgmehri Fard MH, Charkhkar S. Fowl adenoviruses D and E cause inclusion body hepatitis outbreaks in broiler and broiler breeder pullet flocks. *Avian Dis.* 2017;61(2):205-210.
- Steer PA, Kirkpatrick NC, O'Rourke D, Noormohammadi AH. Classification of fowl adenovirus serotypes by use of high-resolution melting-curve analysis of the hexon gene region. *J Clin Microbiol.* 2009;47(2):311-321.
- Kumar S, Stecher G, Tamura K. MEGA7. Molecular evolutionary genetics analysis version 7.0 for bigger datasets. *Mol Biol Evol.* 2016;33(7):1870-4
- Ren G, Wang H, Huang M, Yan Y, Liu F, Chen R. Transcriptome analysis of fowl adenovirus serotype 4 infection in chickens. *Virus Genes.* 2019;55(5):619-629.
- Rahimi, M. and Z.M.S. Haghighi. Adenovirus-like inclusion body hepatitis in a flock of broiler chickens in Kermanshah province, Iran. in *Veterinary Research Forum.* 2015. Faculty of Veterinary Medicine, Urmia University, Urmia, Iran.
- Khodakaram-Tafti A, Asasi K, Namazi F. Clinicopathological characteristics of acute inclusion body hepatitis outbreak in broiler chickens in Iran. *Bulg J Vet Med.* 2016;19(2):163-168.
- Ramis A, Marlasca MJ, Majo N, Ferrer L. Inclusion body hepatitis (IBH) in a group of eclectus parrots (*Eclectus roratus*). *Avian Pathol.* 1992;21(1):165-169.
- Tabib Ghafari P, Boroomand Z, Rezaei A, Mayahi M, Eftekharian S. Detection and identification of avian adenovirus in broiler chickens suspected of inclusion body hepatitis in Khuzestan, Iran during 2015-2016. *Iran J Vet Sci Tech.* 2018;9(2):41-45.
- Hosseini H, Ghalyanchi Langeroudi A, Fallah-Mehrabadi MH, Ziafati Kafi Z, Esmaealzadeh Dizaji R, Ghafouri SA, et al. The fowl adenovirus (Fadv-11) outbreak in Iranian broiler chicken farms: The first full genome characterization and phylogenetic analysis. *Comp Immunol Microbiol Infect Dis.* 2019;70:101365.
- Abghour S, Zro K, Mouahid M, Tahiri F, Tarta M, Berrada J, et al. Isolation and characterization of Fowl aviadenovirus serotype 11 from chickens with inclusion body hepatitis in Morocco. *PLOS One.* 2019;14(12):e0227004.
- Wajid A, Basharat A, Shahid MA, Muntaha ST, Basit A, Hussain T, et al. Molecular characterization and phylogenetic analysis Fowl aviadenovirus isolated from commercial flocks in Pakistan during 2014-15. *Pak J Zool.* 2018;50(5):1863-73.