Iranian Journal of Virology 2024;18(1):29-32.
©2024, Iranian Society of Virology

Short Communication

Avian Infectious Laryngotrachetitis Outbreaks in Iranian Broiler Farms

Naser Sadri[1], Seyed Ahmad Madani[2], Hossein Hosseini[3], Hamideh Najafi[1], Arash GhalyanchiLangeroudi[1*]

1. Department of Microbiology and Immunology, Faculty of Veterinary Medicine, University of Tehran, Tehran, Iran.
2. Department of Animal Nutrition Plant Health , Faculty of Veterinary Medicine, University of Tehran, Tehran, Iran.
3. Department of Clinical Sciences, Faculty of Veterinary Medicine, Karaj Branch, Islamic Azad University, Alborz, Iran.

Abstract

Background and Aims: Infectious laryngotracheitis virus is a member of Gallid alphaherpesvirus 1 causing an acute respiratory infection in chickens throughout the world. The virus lowers normal growth and egg production and leads to economic damages during outbreaks. In Iran, the use of ILT vaccines is restricted to layer poultry farms, and vaccination is not applied in broilers since the outbreaks seldom occur among broilers. Some ILT suspected outbreaks were seen in broiler farms of two provinces of Iran. The present study was conducted to detect the etiologic agent.

Material and methods: Evaluation of clinical signs and gross lesions were performed to diagnose the disease. A PCR test targeting a 113-bp product from the ILTV UL15a gene was carried out to confirm the diagnosis.

Results: The affected chicks represented clinical signs of coughing, sneezing, nasal discharge, gasping, and conjunctivitis with mortality. Hyperemia and bloody mucus in tracheas were observed in post mortem analysis. In the PCR test, samples collected from all of the examined four farms showed the expected 113-bp band size.

Conclusions: The present work for the first time diagnosed ILT outbreak based on a molecular method in broiler chickens kept in Iran. This is an alarming issue according to the intensive population of broilers, hinting an urgent need for more investigations to identify probable ILTVs circulating among broiler poultry farms causing either mild or severe respiratory diseases. Virus isolation and full genome sequencing are required to characterize the viruses. Furthermore, vaccination of pullets against ILT might be effective to control the outbreaks.

Keywords: Avian Infectious Laryngotrachetitis , Broiler, Iran, Outbreak

Introduction

Infectious laryngotracheitis virus is a member of Gallid alphaherpesvirus 1 from the Iltovirus genus causing an acute respiratory infection in chickens throughout the world. The virus lowers normal growth and egg production and leads to economic damages during outbreaks (1). Virulent strains of the virus lead to high mortality, and recovered birds could become latent carriers (2). Clinical signs of the severe form of the disease include depression, gasping, conjunctivitis, nasal discharge, and excretion of bloody mucus. Hemorrhages and mucous plaques could be observed in gross evaluation. The mild form of the disease involves symptoms of mild tracheitis, nasal discharge, swollen infraorbital sinuses, and closed eyes. Goss lesions may have existed in the conjunctiva and respiratory tract, but they are most founded in the larynx and trachea (3).

Virus isolation has been used traditionally to diagnose ILT, but it was time-consuming. Serology has also been described for antibody detection against ILT. However, it has low

[*] **Corresponding author:**
Arash GhalyanchiLangeroudi, Ph.D,
Department of Microbiology and Immunology, Faculty of Veterinary Medicine, University of Tehran, Tehran, Iran.
Email: arashghalyanchi@gmail.com
Email: ghalyana@ut.ac.ir
Tel: +98 2188602205 , Fax: 021 66933222

[Downloaded from journal.isv.org.ir on 2026-11-24]

sensitivity. The next approaches based on polymerase chain reaction have proved effective in investigation of the epidemiology of field ILTV cases. Antigen detection enzyme-linked immunosorbent assay (ELISA) kits are also available (4). Control of ILT is based on vaccination, but as ILT can stablish latent infections, control of the diseases enfaces troubles. There are two kinds of ILTV live attenuated vaccines; Chicken embryo-origin (CEO) vaccines produced by serial passages in embryonated eggs; and Tissue culture-origin (TCO) vaccines attenuated by multiple passages in tissue culture (5). In Iran, the use of vaccines is just limited to layer poultry farms, and the disease rarely has been happened in broilers. In 2019, four outbreaks associated with mortality occurred in two provinces of Iran. Based on a PCR assay, the present study confirmed the presence of ILTV among Iranian broiler farms for the first time.

Methods and Materials

Methods

ILT suspected outbreaks have occurred broiler farms (population varied from 30,000 to 50,000 birds) of two central provinces of Iran in 2019. 27 to 53 day-old commercial broilers in three farms in Semnan province and one farm in Markazi province showed severe signs of respiratory involvement associated with mortality. While hemorrhage and hyperemia were evident in tracheas at necropsy, there was no abnormal finding in the lower respiratory tract, including the lung. Samples of tracheal tissues from five birds per flock were collected.

DNA extraction and PCR

DNA was isolated from tracheal tissues using the CinnaPure DNA extraction kit (Cat. No.: PR881613). A previously described PCR assay was used to amplify a 113-bp product from the ILTV UL15a gene (4). Briefly, 3 µl of DNA was added to PCR mix containing 1 µl of each UL15a Forward (5'-TTGCTGTGCTATTTCG-CGTG-3') and UL15a Reverse (5'-GTAAAT-CGTTTAGTGCGGCAT-3') and reversed primers, 2 µl of distilled water, and 13 µl of SinaClon 2x PCR master mix (SinaClon, Iran, Cat. No.: MM2061). Initial denaturation was performed at 95℃ for 2 min, following by 35 cycles of denaturation at 95℃ for 15 s, annealing at 62℃ for 30 s and polymerization at 72℃ for 20 s , and proceed by 72℃ for 7 min. PCR products were separated by electrophoresis in 1.5% agarose gel, and the bands were envisioned under UV light.

Results

The affected chicks represented clinical signs of coughing, sneezing, nasal discharge, gasping, and conjunctivitis with mortality. Hyperemia and bloody mucus in tracheas were observed in post mortem analysis. In the PCR test, samples collected from all of the examined four farms showed the expected 113-bp band size (Figure 1).

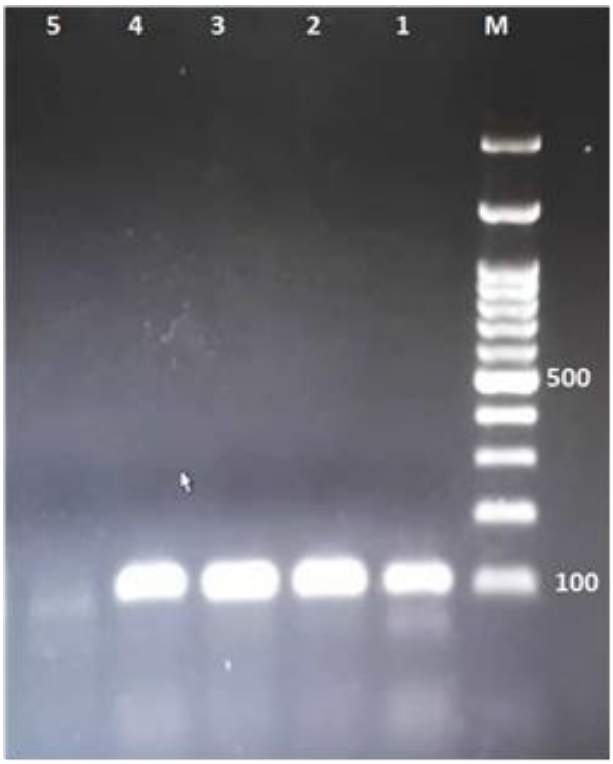

Fig. 1. Lane M: 100-bp ladder, Lane 1 to 4: contains PCR products from tracheal samples obtained from flocks 1 to four showing 113-bp band size, Lane 5: negative control.

Discussion

ILT is an acute upper respiratory infection of

[Downloaded from journal.isv.org.ir on 2026-11-24]

chicken, having great economic consequences in the whole world poultry industry. The disease was primarily reported in 1925 from the United States. While chickens are the major host of the virus, pheasants can also be affected. The virus can be disseminated via respiratory and ocular routs, and because of the biologic features, it could persist in the affected birds and regions in its endemic form.

Although the virus can infect chicks of all ages, birds older than three weeks are more susceptible (3). In Iran, the use of ILT vaccines is restricted to layer poultry farms, and vaccination is not applied in broilers since the outbreaks seldom occur among broilers. In some parts of the world, ILTV is found in intensive broiler production regions and leads to highly contagious upper respiratory infection in chickens [6]. An ILT outbreak in broilers was related to the one that occurred in the United States in which the poultry farm suffered increased daily mortality (20-200 birds). ILTV was diagnosed based on clinical signs, gross descriptions, and PCR assay (7).

Shehata et al. isolated four field strains of ILTV from cross-breed broiler chickens in Egypt (8). During 1992, ILTV was detected from broiler flocks of California. Some flocks were losing up to 100 birds per day. Birds were not vaccinated against ILT, and they showed swollen eyes, wheezing, gasping, and blood material in the trachea (9). ILTV was also detected among broiler flocks in the southeastern United States during 2001[10]. From 2007 to 2009, ILTV was isolated from broiler and layer poultry farms of Australia, showing respiratory signs of ILT, associated with mortality (11). Out of 189 cases collected between 1999-2010 in Poland, 3.2% of broiler chickens with a mean age of 37 days and 4.8% of layers with a mean age of 196 days were ILTV positive in histopathology analysis (12). Out of 60 commercial broiler and layer farms tested in India, 42 found to be positive for ILTV by PCR (13). In a screening project carried out in Pakistan between 2014 and 2016, 161 oropharyngeal swabs or tracheal tissue impression smears were collected from 98 commercial broiler and layer farms. The PCR results for ILTV detection were negative (14).

ILT outbreaks severally have been reported in layer and breeder flocks in Iran since 1994 (15, 16). Aghakhan et al. explained the ILT outbreak in commercial poultry, especially layer and breeder flocks (15). In an investigation on 17 commercial layer flocks from different provinces of Iran during 2003, 82.3 % of flocks were found to be ILT positive in a PCR technique (16). Furthermore, there was a report on ILT outbreak in layer farms after vaccination (2000) (17).

Despite the existence of various reports on the ILT outbreak in broiler farms of different parts of the world, the disease rarely occurred in Iranian broiler farms. The present work for the first time diagnosed ILT outbreak based on a molecular method in broiler chickens kept in Iran. More investigations are needed to identify probable ILTVs circulating among broiler poultry farms, causing either mild or severe respiratory diseases. Virus isolation and full genome sequencing are required to characterize the viruses. Furthermore, vaccination of pullets against ILT might be effective to control the outbreaks.

Acknowledgment

We acknowledge from Behrooz Asadi for his technical supports.

Disclosure

None

Conflict of Interest

No conflict of interest is declared.

Funding

None

Ethics Approval and Consent to Participate

None

Data Availability Statement

[Downloaded from journal.isv.org.ir on 2026-11-24]

All data generated or analyzed during this study are included in this article.

References

1. Oldoni I, Rodriguez-Avila A, Riblet SM, Zavala G, Garcia M. Pathogenicity and growth characteristics of selected infectious laryngotracheitis virus strains from the United States. Avian Pathol. 2009;38(1):47-53.
2. Creelan JL, Calvert VM, Graham DA, McCullough SJ. Rapid detection and characterization from field cases of infectious laryngotracheitis virus by real-time polymerase chain reaction and restriction fragment length polymorphism. Avian Pathol. 2006;35(02):173-9.
3. Kaur J, Brar RS, Leishangthem GD, Banga HS, Singh ND. Immunohistopathological studies on infectious laryngotracheitis disease in poultry birds (Immunohistopathological studies on infectious laryngotracheitis disease). J Entomol Zool Stud. 2019;7(3):212-6.
4. Mahmoudian A, Kirkpatrick NC, Coppo M, Lee SW, Devlin JM, Markham PF, et al. Development of a SYBR Green quantitative polymerase chain reaction assay for rapid detection and quantification of infectious laryngotracheitis virus. Avian pathol. 2011;40(3):237-42.
5. Gelenczei E, Marty E. Studies on a tissue-culture-modified infectious laryngotracheitis virus. Avian Dis. 1964;8(1):105-22.
6. Portz C, Beltrão N, Furian TQ, Júnior AB, Macagnan M, Griebeler J, et al. Natural infection of turkeys by infectious laryngotracheitis virus. Vet Microbiol. 2008; 131(1-2):57-64.
7. Dormitorio TV, Giambrone JJ, Macklin KS. Detection and isolation of infectious laryngotracheitis virus on a broiler farm after a disease outbreak. Avian Dis. 2013;57(4):803-7.
8. Shehata AA, Halami MY, Sultan HH, El-Razik AGA, Vahlenkamp TW. Chicken embryo origin-like strains are responsible for Infectious laryngotracheitis virus outbreaks in Egyptian cross-bred broiler chickens. Virus Genes. 2013;46(3):423-30.
9. Linares JA, Bickford AA, Cooper GL, Charlton BR, Woolcock PR. An outbreak of infectious laryngotracheitis in California broilers. Avian Dis. 1994;38(1): 188-92.
10. Sellers HS, García M, Glisson JR, Brown TP, Sander JS, Guy JS. Mild infectious laryngotracheitis in broilers in the southeast. Avian Dis. 2004;48(2):430-6.
11. Blacker HP, Kirkpatrick NC, Rubite A, O'Rourke D, Noormohammadi AH. Epidemiology of recent outbreaks of infectious laryngotracheitis in poultry in Australia. Aust Vet J. 2011;89(3):89-94.
12. Dolka I, Sapierzyński R, Bielecki W, Malicka E, Żbikowski A, Szeleszczuk P. Histopathology in diagnosis of broiler chicken and layer diseases–review of cases 1999-2010. Pol J Vet Sci. 2012;15(4):773-9.
13. Sivaseelan S, Rajan T, Malmarugan S, Balasubramaniam G, Madheswaran R. Tissue tropism and pathobiology of infectious laryngotracheitis virus in natural cases of chickens. Isr J Vet Med. 2014;69(4):197-202.
14. Umar S, Teillaud A, Aslam HB, Guerin JL, Ducatez MF. Molecular epidemiology of respiratory viruses in commercial chicken flocks in Pakistan from 2014 through to 2016. BMC Vet Res. 2019;15(1):351.
15. Aghakhan SM, Abshar N, Nejad Fereidouni SR, Marunesi C, Khodashenas M. Studies on avian viral infections in Iran. Arch Razi Ins. 1994;44/45:1-10.
16. Ebrahimi MM, Pourbakhsh SA, Shahsavandi S, Momayez R, Gholami MR. Isolation and identification of infectious laryngotrachitis virus from commercial flocks of Iran using various techniques. Arch Razi Ins. 2003;56:11-22.
17. Ebrahimi MM, Shahsavandi S, Pourbakhsh SA, Gholami MR. Outbreak of infectious laryngotracheitis following vaccination in pullet flock. Arch Razi Ins. 2001;52:19-26.

[Downloaded from journal.isv.org.ir on 2026-11-24]