

## Original Article

# Immunosuppression Viral Diseases in Healthy Broiler Flocks: The Pilot Study

Arash Ghalyanchi-Langeroudi<sup>1</sup>, Seyed Ahmad Madani<sup>2</sup>, Naser Sadri<sup>1</sup>,  
Zahra Ziafatikafi<sup>1</sup>, Soroush Sarmadi<sup>1</sup>, fahimeh Jamiri<sup>1</sup>, Alireza Bakhshi<sup>1</sup>,  
Omid Eghbali<sup>1</sup>, Hossein Hosseini<sup>3\*</sup>

1. Department of Microbiology and Immunology, Faculty of Veterinary Medicine, University of Tehran, Tehran, Iran.
2. Department of Animal and Poultry Health and Nutrition, Faculty of Veterinary Medicine, University of Tehran, Tehran, Iran.
3. Department of Clinical Sciences, Faculty of Veterinary Medicine, Karaj Branch, Islamic Azad University, Alborz, Iran.

## Abstract

**Background and Aims:** Immunosuppressive viral diseases have become a significant reason for mortality and economic losses in the poultry industry, mainly because of the increased susceptibility of to second bacterial infections and low responses to vaccination. The aim of this study, was to investigate the immunosuppressive viral agent, including IBDV, IBV, MDV, FadV, NDV, AIV, and CAV, in healthy farms. Bursas samples were collected from 3-4 week old broilers farm without clinical signs. One part of bursas fixed by immersion in 10% buffered formalin for histopathologic study and other parts selected for molecular studies. The RNA and DNA were extracted. PCR and RT-PCR were performed for this RNA and DNA viruses, respectively, and Phylogenetic analysis was conducted for IBD positive samples, also fixed tissue prepared for the histopathological purpose. Generally, four samples of 12 bursas samples were IBDV positive, five samples IBV positive (%41.66), and two samples MDV positive (16.66%).

Interestingly these four IBDV positive samples showed the histopathological changes described above. According to the results of PCR and histopathology determine that % 33.33 of broilers farm in Iran are suffering from subclinical IBD. All samples for AIV, NDV, CAV, and IBH were negative in PCR detection methods. The phylogenic tree analysis results show that these sequences are similar to other IBDV strains circulating in Iran broiler farms and belong to very virulent IBDV genogroups.

**Keywords:** Immunosuppression, Infectious bursal disease, Histopathology, PCR, Bursa of Fabricius.

## Introduction

One of the biggest problems in the poultry industry is a complex respiratory disease and vaccination failure due to immunosuppression. Immunosuppressed chickens are more sensitive to secondary infection, respond defectively to vaccination, show higher feed conversion ratio (FCR), reduced daily weight

gain, and cause significant economic losses due to the cost of antibiotics used to control secondary infections and carcass condemnations. While vaccination against respiratory sophisticated disease agent was wholly done, the level of immunity was very low in some farms.

Several factors can affect the immune system such as immunosuppressive viruses, including Marek's disease virus (MDV), Infectious Bursal disease virus (IBDV), chicken infectious anemia virus (CAV), Newcastle disease virus (NDV), infectious bronchitis virus (IBV), Avian Influenza virus (AIV), reticuloendotheliosis (REV), and Fowl Adenovirus (FadV), in other hands some environmental factor such as expo-

\* Corresponding author;

Hosseini Hossein, Ph.D

Email: hosseini.ho@gmail.com

sure to Ammonia and Formaldehyde, and other factors such as mycotoxins (Aflatoxin, Trichothecenes, Ochratoxins, etc.) (1). The characteristic symptoms obtained by these viruses differ, and some symptoms are not easily obvious. The pathological analysis of lymphoid organs is simply practicable. The use of quantitative signs may largely provide a more fast and accurate diagnosis. Lymphoid organs sections (bursa, thymus, and spleen) contribute to objective evaluation (2, 3). A histopathological investigation is an important tool for evaluating the severity of immunosuppression and discriminating between several diseases (4). The bursa of Fabricius of broilers is the initial target organ of IBDV. The virus replicates in IgM+ B cells and leads to a depletion of these cells in the BF, suppressing the humoral immune system. Cellular immunity is also endangered during an IBDV infection (5). For diagnosis, detection of immunosuppression agents mainly focuses on detecting specific diseases by virus isolation, or molecular detection of the etiologic agent, or possible lesions recognized at necropsy or histopathology (6).

The aims of this study, was to investigate the immunosuppressive viral agent including IB-DV, IBV, MDV, FadV, NDV, AIV, and CAV in healthy farms with focussing on histopathological and molecular detection and determine the percentage of each agent in these farms.

## Methods and Materials

### Sampling

Bursas samples were collected from 3-4 week old broilers farm without clinical signs. Each specimen was divided into two sections from the middle part. One part was fixed by immersion in 10% buffered formalin for histopathologic purposes, and other parts were selected for molecular studies and kept at -20 °C.

### Histopathology

For this purpose, fixed tissues were prepared for paraffin embedding, sectioned, and stained with H&E following standard methods.

### RNA/DNA Extraction

The bursas tissue was homogenized, and Viral

DNA and RNA were extracted by the Sina Pure DNA kit and Cinna Pure RNA extraction kit (Cinnaclon Co., Iran) according to the manufacturer's protocol. The extracted DNA and RNA were stored at -20°C for the consequent PCR process.

### RT

For cDNA synthesis, 1µL of random hexamer primer (SinaClon, Iran) was added to 10 µL of RNA. The mixture was incubated 5 minutes at 65°C and 1 minute at 5°C. 11 µL of Master mix including 2.25 µL of Distilled water (SinaClon, Iran), 2 µL of dNTP (SinaClon, Iran), 0.25 µL of RiboLock RNase Inhibitor (Thermo Fisher Scientific, USA), 0.5 µL of Revert Aid Reverse Transcriptase (Thermo Fisher Scientific, USA), and 4 µL of 5X RT reaction buffer was added to each tube, resulting in a final volume of 20 µL. Next, the microtube was incubated at 25 °C for 5 minutes, 42 °C for 1 hour, and 95 °C for 5 minutes. The cDNA was stored at -18 °C.

### PCR

PCR was conducted in BIO-RAD T100 PCR Thermal Cycler with 2.5 µL of templet in a total 25 µL volume of a reaction containing 1 µL of each primer and 8 µL DNase free water, and 12.5 µL of 2x PCR Master Mix Red (Maxell). The reactions were carried out according to primers and annealing temperature showed in Table 1. The PCR products were separated by electrophoresis in 1.5 % agarose gels and visualized by UV light.

### Sequencing and Phylogenetic Study

Takapouzi sequenced the IBDV Positive PCR products. Multiple sequence alignments were conducted with ClustalW, and a phylogenetic tree was created with MEGA 7 software using the neighbor-joining method with 1000 bootstrap replicates (7). The IBD sequences were compared with reference and Iranian strains

## Results

**Table 1.** Sequences of primers used in this study and the annealing and lengths of amplicons.

virus	Gene	Primer	sequence	Annealing	Ampliqon size
Infectious bursal disease virus	VP2			48	
Infectious bronchitis virus (Nested PCR)	S1	SX1	CACCTAGAGGTTTGYTWGCATG	48	494
		SX2	TCCACCTCTATAAACACCCYTTAC		
	S1	Sx3	TAATACTGGYAATTTTTCAGATGG	48	390
		SX4	AATACAGATTGCTTACAACCACC		
Marek's disease virus	gB	MD gdF	TCCAATACACCAACATCAC	50	275
		MD gdRm	CAAGGAAACATACAGGGAC		
Chicken infectious anemia virus	VP2-VP3		CAGTGAATCGGCGCTTAGC	55	452
			GCTCGTCTTGCCATCTTACAG		
Avian Influenza virus (Nested PCR)	H9	H9F	CTYCACACAGARCACAATGG	49	488
		H9R	GTCACACTTGTGTGTRTC		
	H9	H9F2	TCTTCCCAGACACAATCTGGAA	52	230
		H9R2	TGTTGTTGTGTCGGTCTTGTGT		
Newcastle disease virus	F	NDCreF	GGTGAGTCTATCCGGARGATACAAG	48	203
		NDCreR	TCATTGGTTGCRGCAATGCTCT		
Inclusion body hepatitis	Hexon	IBH F	ATGGGAGCSACCTAYTTGACAT	56	593
		IBH R	AAATTGTCCCKRAANCCGATGTA		

**Table2.** The results of PCR and RT-PCR of different viral diseases on the bursa Fabricius of broiler samples.

Flocks	Infectious Bronchitis	Avian Influenza	Newcastle Disease	Infectious Bursal Disease	Fowl Adenovirus	Chicken Anemia Virus	Marek Disease	Histopathology (Degree of Depletion)
B1	+	-	-	+	-	-	-	Sever
B2	+	-	-	-	-	-	-	Mild
B3	-	-	-	-	-	-	-	Mild
B4	+	-	-	+	-	-	-	Sever
B5	-	-	-	-	-	-	-	Mild
B6	-	-	-	-	-	-	-	Moderate
B7	+	-	-	+	-	-	+	Sever
B8	-	-	-	-	-	-	+	Mild
B9	-	-	-	-	-	-	-	Sever
B10	+	-	-	+	-	-	-	Sever
B11	-	-	-	-	-	-	-	Mild
B12	-	-	-	-	-	-	-	Mild

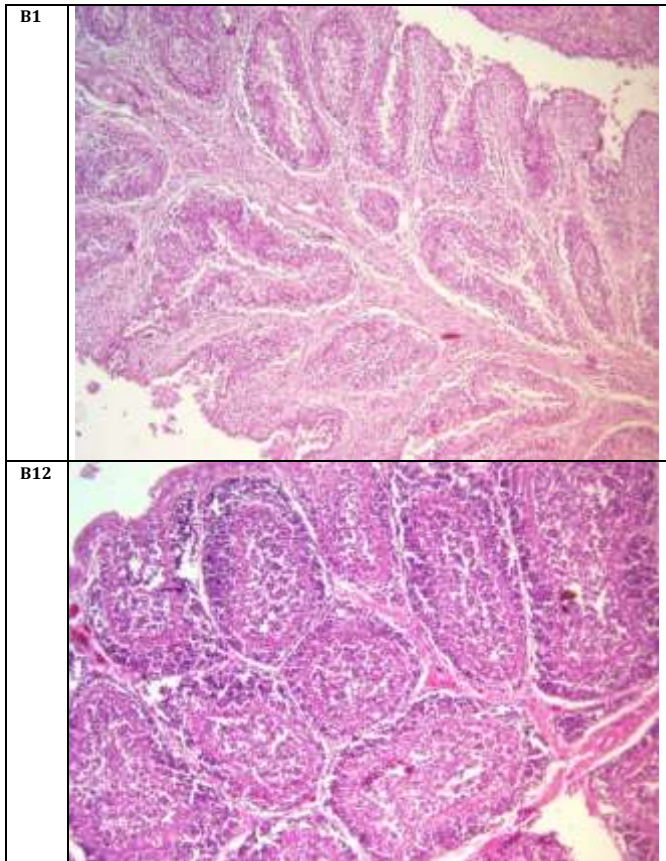
**Histopathology**

A total of 12 samples were collected from healthy broiler farms; Histopathologically, Four samples showed lymphoid depletion in bursa tissue (Figure1). The scoring of the different IBD lesions in the bursa of Fabricius was done

by a pathologist, as noted in Table2.

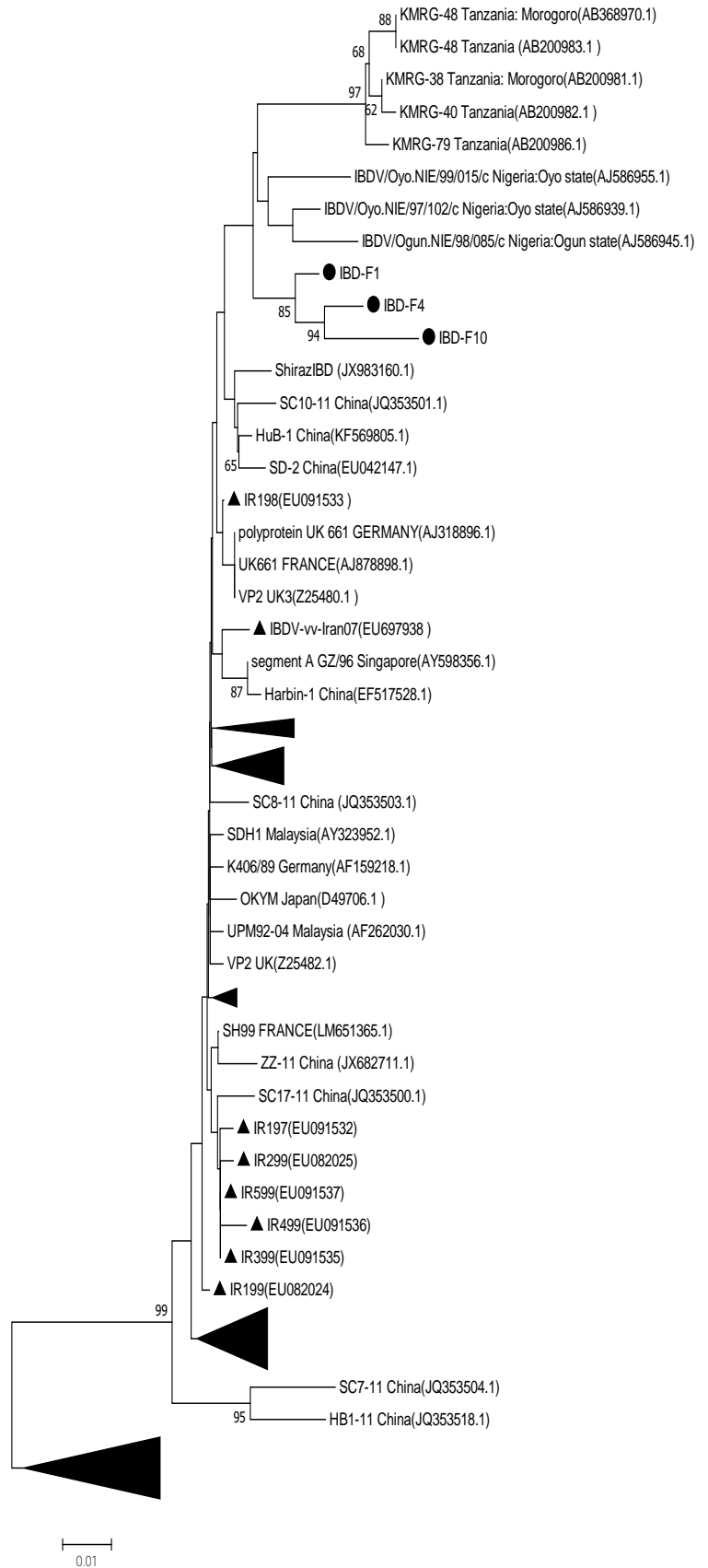
**PCR and phylogenic analysis**

Generally, four samples of 12 bursas samples were IBDV positive, five samples IBV positive (%41.66), and two samples MDV positive



**Fig 1.** Histopathology of the bursa of Fabricius of chickens in different flocks (B7; B12; B6). **B1.** IBD positive; IB Positive Severe depletion. **B12.** No agents detected. Mild depletion.

**Fig 2.** Phylogenetic tree of *Vp2* of the Infectious Bursal Disease Virus (IBD) detected in Iran. The phylogenetic tree was constructed using MEGA version 7 by the neighbor-joining method with 1000 bootstrap replicates (bootstrap values are shown on the tree). The tree is drawn to scale, with branch lengths in the same units as those of the evolutionary distances used to infer the phylogenetic tree. The evolutionary distances were computed using the Kimura 2-parameter method (black circle: Iranian IBDv samples in the current study; black triangles: Iranian IBDv samples in other studies)



(%16.66) (Table1). Interestingly this 4 IBDV positive sample shown the histopathological changes described above. According to the results of PCR and histopathology, it was found that % 33.33 of broilers farm in Iran suffers from subclinical IBD, which could be one reason for vaccination failure and low immunity in these population.

All samples for AIV, NDV, CAV, and IBH were negative by PCR detection methods. The

phylogenetic tree analysis results showed that these sequences were similar to other IBDV strains circulating in Iran broiler farms and

belong to very virulent IBDV genogroups (Figure 2).

### Discussion

Immunosuppression is a general situation in intensive broiler breeding, where stress factors are various and continually present. This study proposed to determine the prevalence of exposure to MDV, IBDV, FAdV, NDV, AIV, and CAV among Iran's commercial broiler flocks during grow-out to determine the most prevalent genotypes of subclinical IBDV, and find out if there was data for coinfection between exposure to IBDV and exposure to the other viruses. This study showed that % 33.33 of broiler flock in Iran were IBD positive with PCR, which can cause immunosuppression and vaccine failure. Commonly IBD can moderate suppression when chickens were contaminated at seven days and negligible effects when infection was 14 to 21 days with reduced humoral antibody response to other vaccines(8). The occurrence of poultry diseases varies with season. However, inhibition of immunosuppressive diseases (IBD and Mycotoxicoses) may decrease the occurrence of other diseases (9). In this study, four farms were positive simultaneously by IBD and IBV, demonstrating that IBD may cause immunosuppression for secondary infection by other pathogens. Aflatoxin and IBDV do not significantly alter the immune response of backyard chickens to ND vaccination(10). The IBDV strains circulating in Iran broiler farms belong to highly virulent IBD strains (11, 12); the results of our phylogenetic analysis have also shown that these strains are very similar to the existing subclinical strains of Iran belonging to highly virulent strains. Given two positive samples for MDV in this study, and according to the Iranian Veterinary Organization based on no vaccination against Marek's disease in broiler farms, we conclude that these samples are not vaccine strains and can be a pathogenic nonpathogenic strain. The results of recent researches confirm it(11). The pathological study can define the immunosuppression effect of Marek's disease in broiler farms(12). CAV principally affects the cellu-

lar immune system. B cells are not sensitive to CAV infection and are not directly affected by this virus. CAV replicates in lymphocytes, destroying thymic lymphocytes, and is directly cytotoxic for bone marrow; There is a decrease in weight and size of lymphoid organs, such as the thymus, bursa, and spleen(13). hanif *et al.* (14) showed close cooperation of Ochratoxin A with infectious diseases such as ND, HPS(hydropericardium syndrome), and IBD, which cause significant suppression of the humoral immune system. Pre-infection with CAV in broiler chickens can provide to the spread and evolution of AIV and IBV(15). a decreased serological response was inspected against AIV in the presence of FadV infection in chicken compared to the serological response against AIV from healthy birds (16).

### Conclusions

We found that Iran broiler farms were frequently exposed to IBDV, MDV, and IBV. This study also identified potentially very virulent genotypes of IBDV that can guide vaccination strategy and disease control applications in Iran. Flocks that were primarily exposed to subclinical IBDV will most probably be exposed to IBV, MDV, or other secondary infections.

### Acknowledgment

The authors would like to thank the PCR Veterinary Diagnostic Laboratory and Ghalyanchi Laboratory experts for their technical support.

### Conflict of Interest

No conflict of interest is declared.

### Funding

There are no undisclosed sources of funding for either our research or our manuscript itself.

## Ethics Approval and Consent to Participate

This article does not contain any studies with human participants or animals performed by any authors.

## References

1. Hoerr FJ. Clinical aspects of immunosuppression in poultry. *Avian Dis.* 2010;54(1):2-15.
2. Halouzka R, Jurajda V. Morphological expression of immunosuppression in poultry. *Acta Vet Brno.* 1991;60(3):271-6.
3. Sellaoui S, Alloui N, Mehenaoui S, Djaaba S. Evaluation of size and lesion scores of bursa cloacae in broiler flocks in Algeria. *J World's Poult Res.* 2012;2(2):37-9.
4. Pope CR. Pathology of lymphoid organs with emphasis on immunosuppression. *Vet Immunol Immunopathol.* 1991;30(1):31-44.
5. Rautenschlein S, Yeh HY, Njenga MK, Sharma JM. Role of intrabursal T cells in infectious bursal disease virus (IBDV) infection: T cells promote viral clearance but delay follicular recovery. *Arch Virol.* 2002;147(2):285-304.
6. Dietert RR, Golemboski KA, Austic RE. Environment-immune interactions. *Poul Sci.* 1994;73(7):1062-76.
7. Kumar S, Stecher G, Tamura K. MEGA7: Molecular Evolutionary Genetics Analysis Version 7.0 for Bigger Datasets. *Mol Biol Evol.* 2016;33(7):1870-4.
8. Faragher JT, Allan WH, Wyeth PJ. Immunosuppressive effect of infectious bursal agent on vaccination against Newcastle disease. *Vet Rec.* 1974;95(17):385-8.
9. Amit S, Purushottam T. Seasonal Prevalence of Poultry Diseases and their interaction with IBD and Mycotoxicosis in Chitwan, Nepal. *The Research Gate.* 2015.
10. Otim MO, Mukibi-Muka G, Christensen H, Bisgaard M. Aflatoxicosis, infectious bursal disease and immune response to Newcastle disease vaccination in rural chickens. *Avian Pathol.* 2005;34(4):319-23.
11. Nabinejad A. Study on Subclinical and Clinical Marek's Disease (MD) in the Broiler Chickens Using Histopathology. *Int J Adv Biol Biom Res.* 2013;1(8):795-801.
12. Abreu DLC, Santos FF, José DS, Tortelly R, Nascimento ER, Pereira VLA. Pathological aspects of a subclinical marek's disease case in free-range chickens. *Braz J Poul Sci.* 2016;18(1):197-200.
13. Adair BM. Immunopathogenesis of chicken anemia virus infection. *Dev Comp Immunol.* 2000;24(2-3):247-55.
14. Hanif NQ, Muhammad G. Immunotoxicity of ochratoxin A and role of *Trichosporon* mycotoxinivorans on the humoral response to infectious viral disease vaccines in broilers. *Pak J Zool.* 2015;47(6):1683-9.
15. Erfan AM, Selim AA, Helmy SA, Eriksson P, Naguib MM. Chicken anaemia virus enhances and prolongs subsequent avian influenza (H9N2) and infectious bronchitis viral infections. *Vet Microbiol.* 2019;230:123-9.
16. Rashid F, Abbas MA, Siddique N, Rafique S, Ahmed S, Mehmood F, et al. Induction of immunosuppression in broiler chicken upon co-infection of avian adenovirus-4 with low pathogenic avian influenza H9N2. *Pak Vet J.* 2017;37(3):311-5.